

TEMA XII y XIII

OPERATORIA EN MOLARES TEMPORALES




Prf^a. A. Mendoza Mendoza

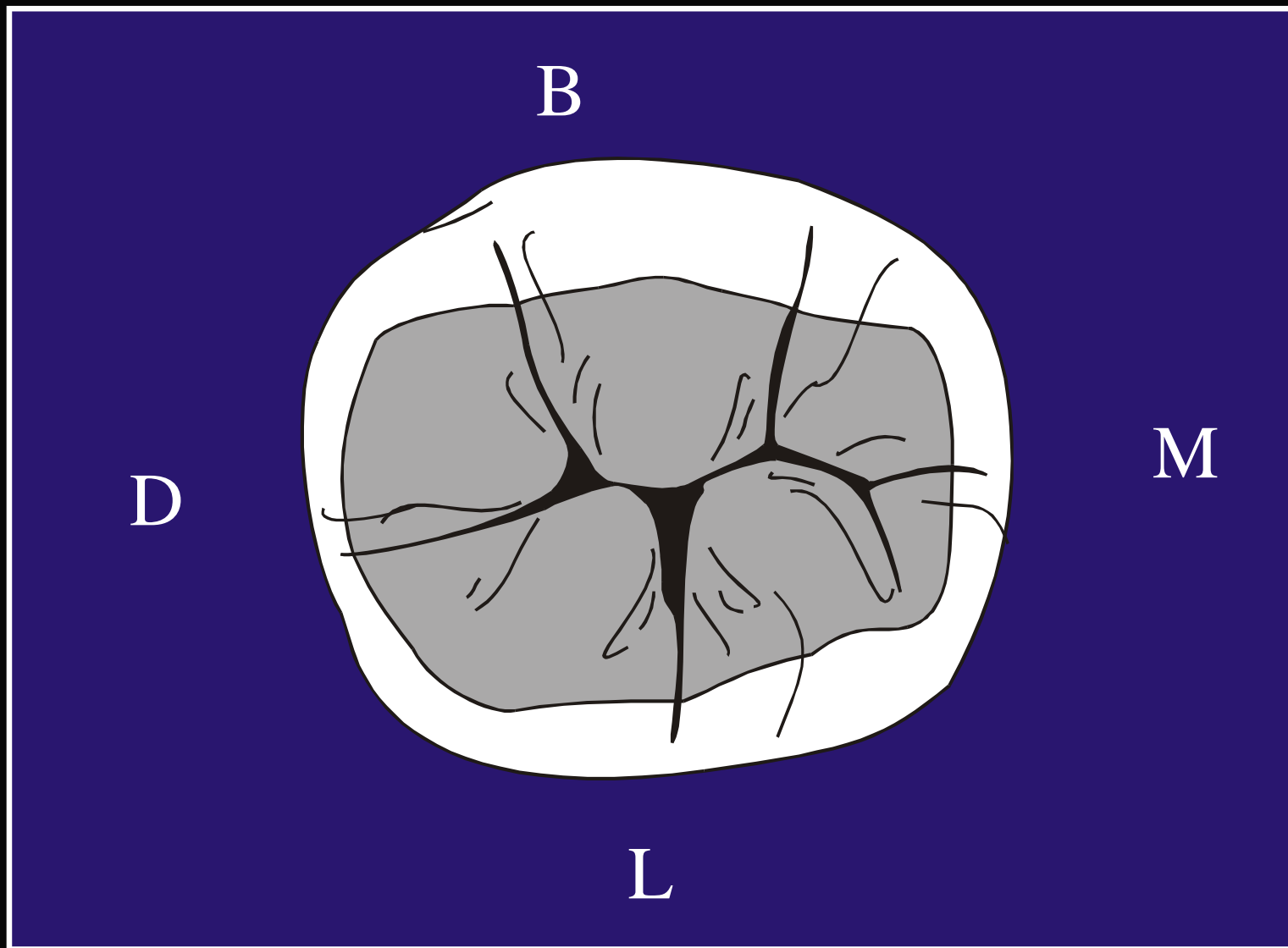
CAVITARIAS

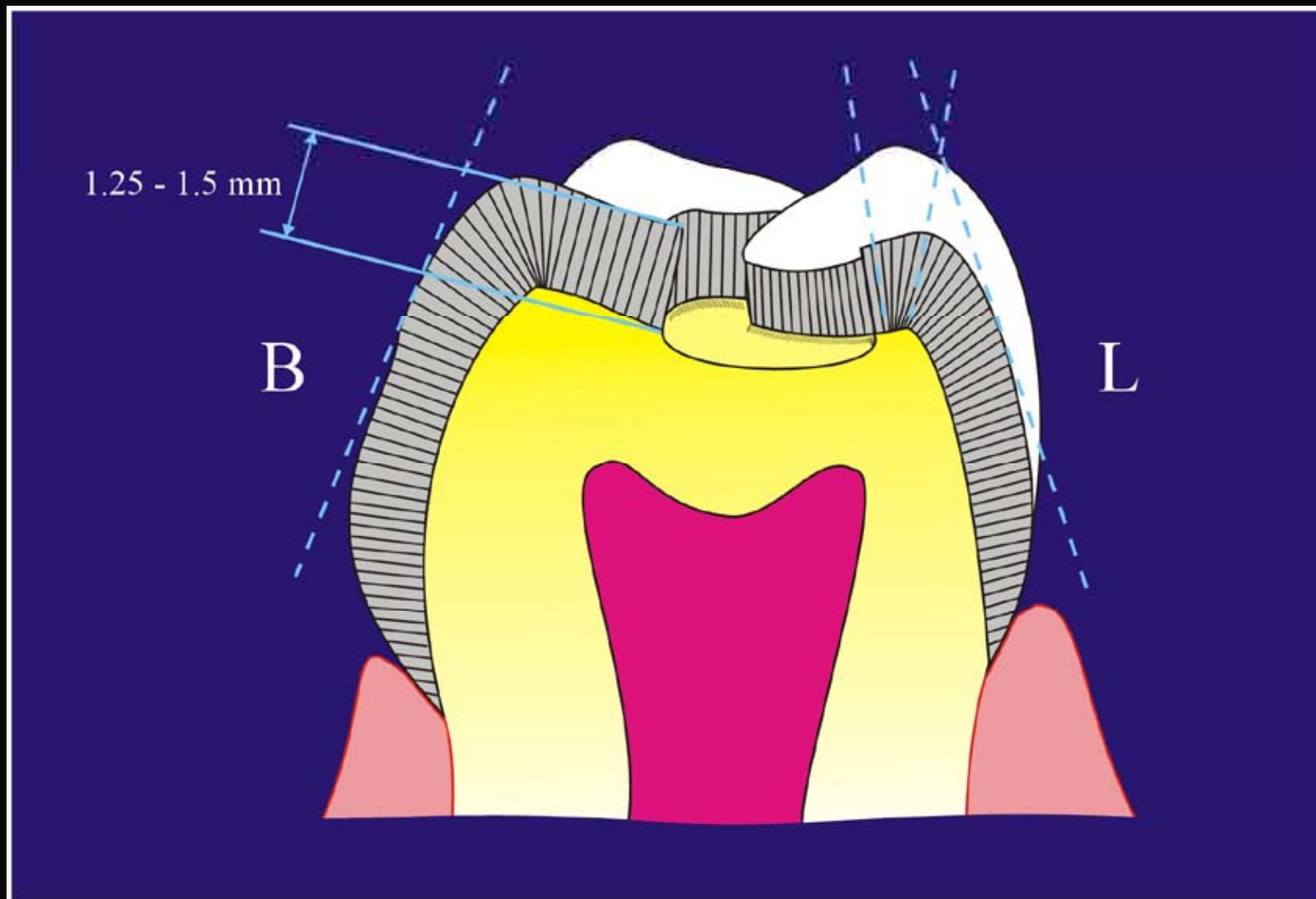
CLASE I

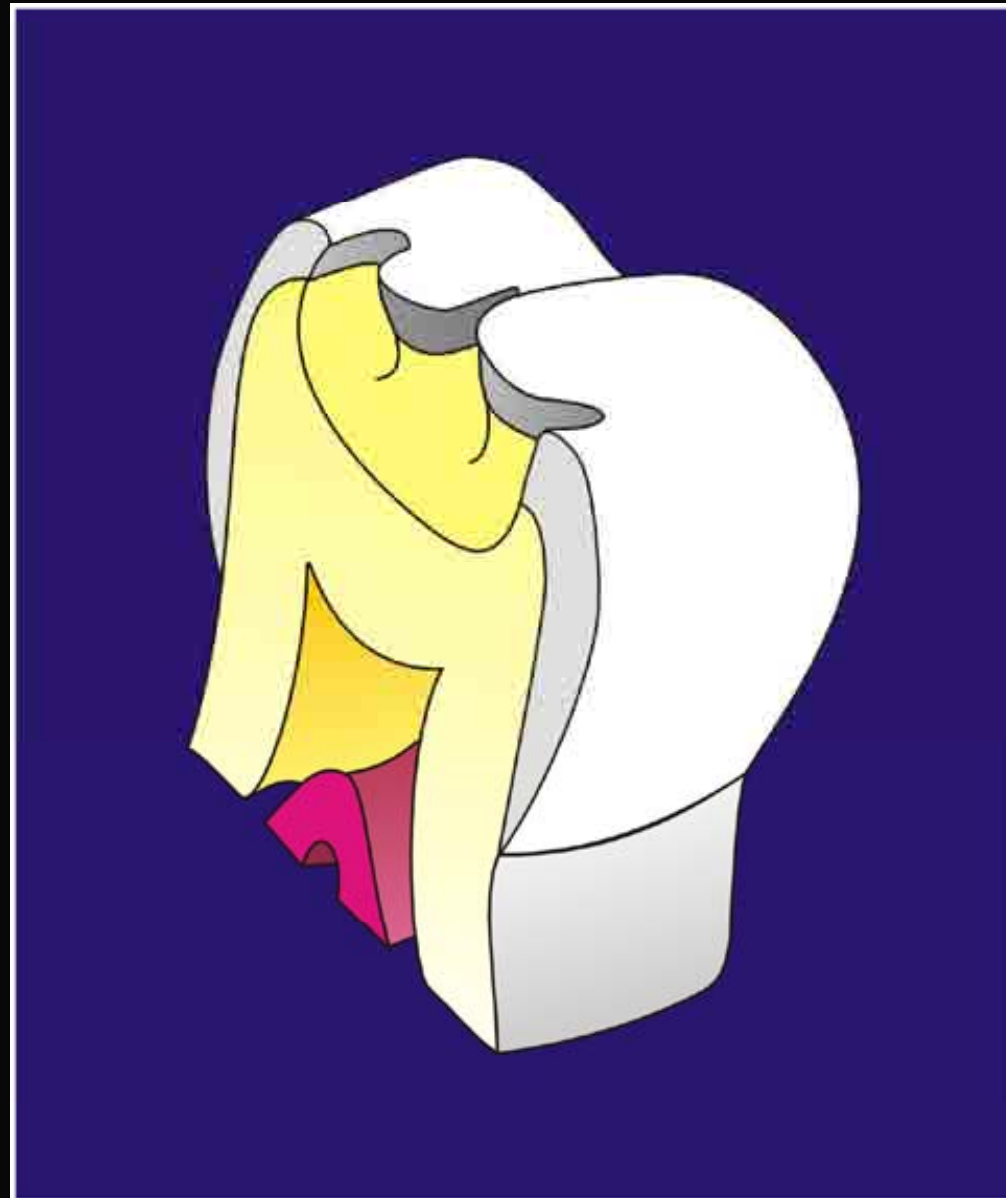
FRESA 330

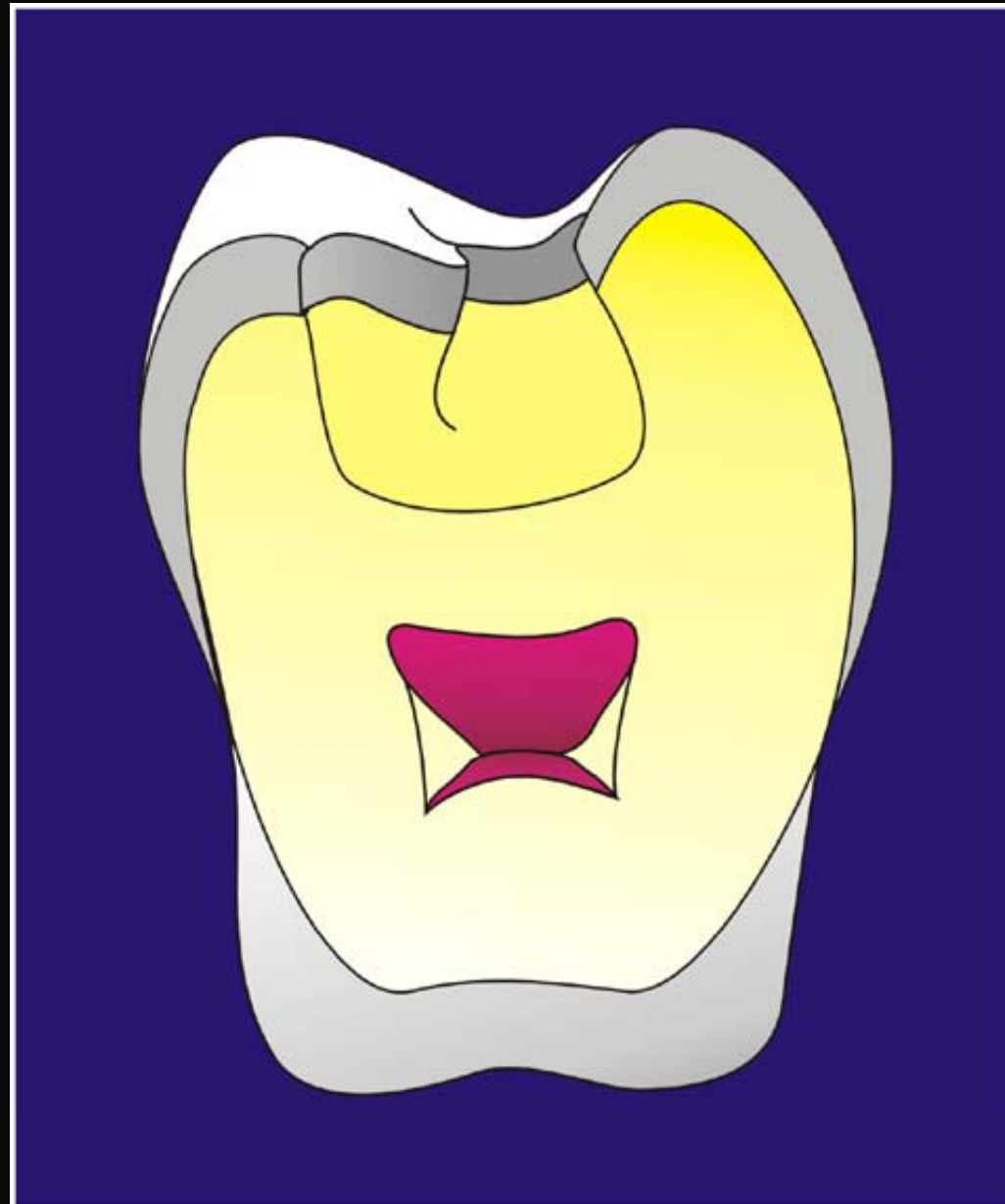

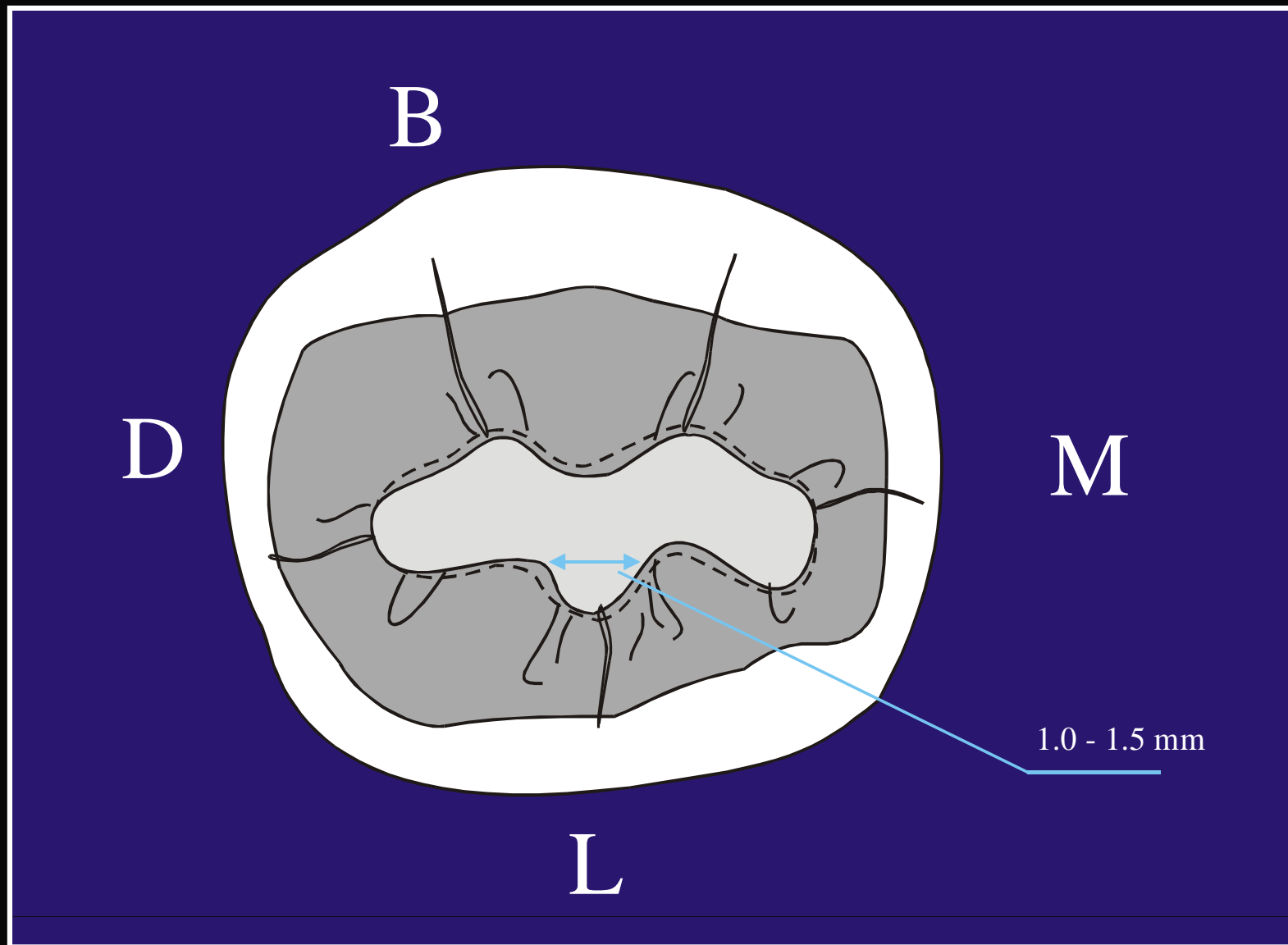
SEGUNDO MOLAR TEMPORAL INFERIOR



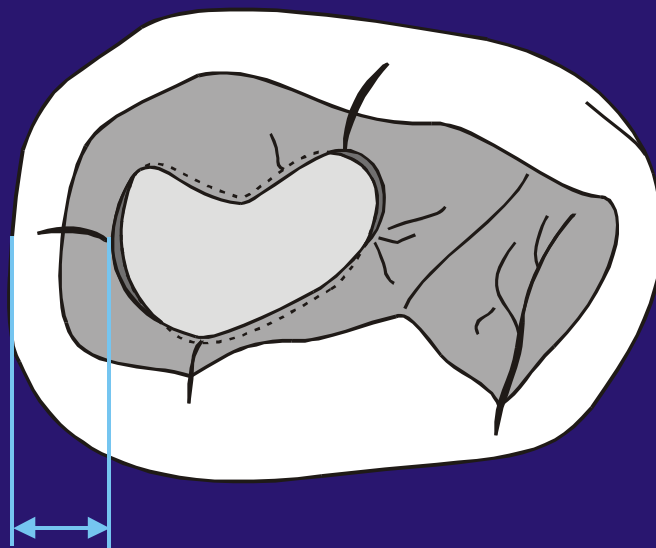






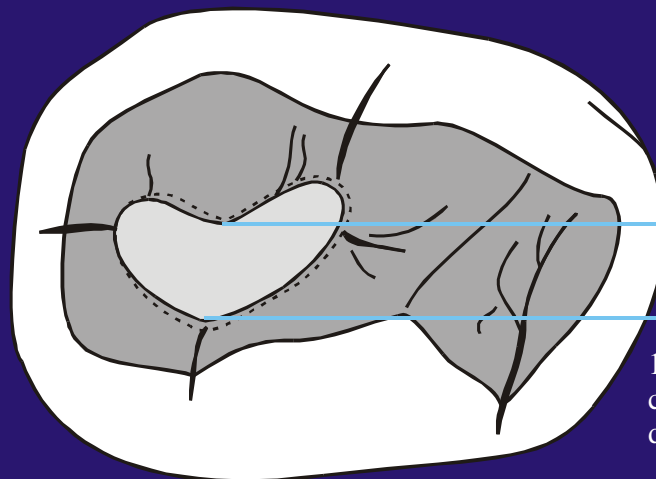


**PRIMER MOLAR
TEMPORAL INFERIOR**



1.25 mm

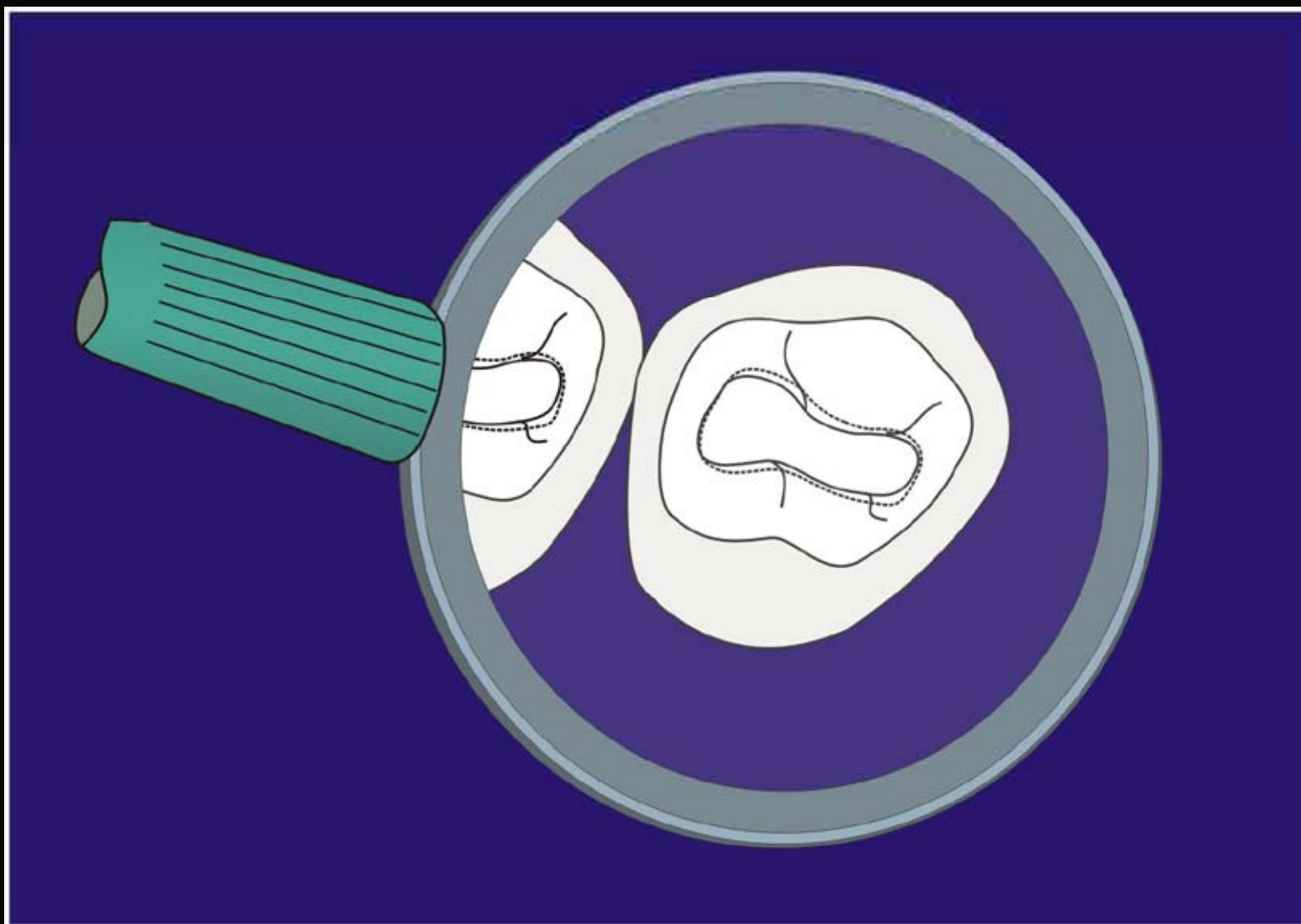
Máxima Preparación



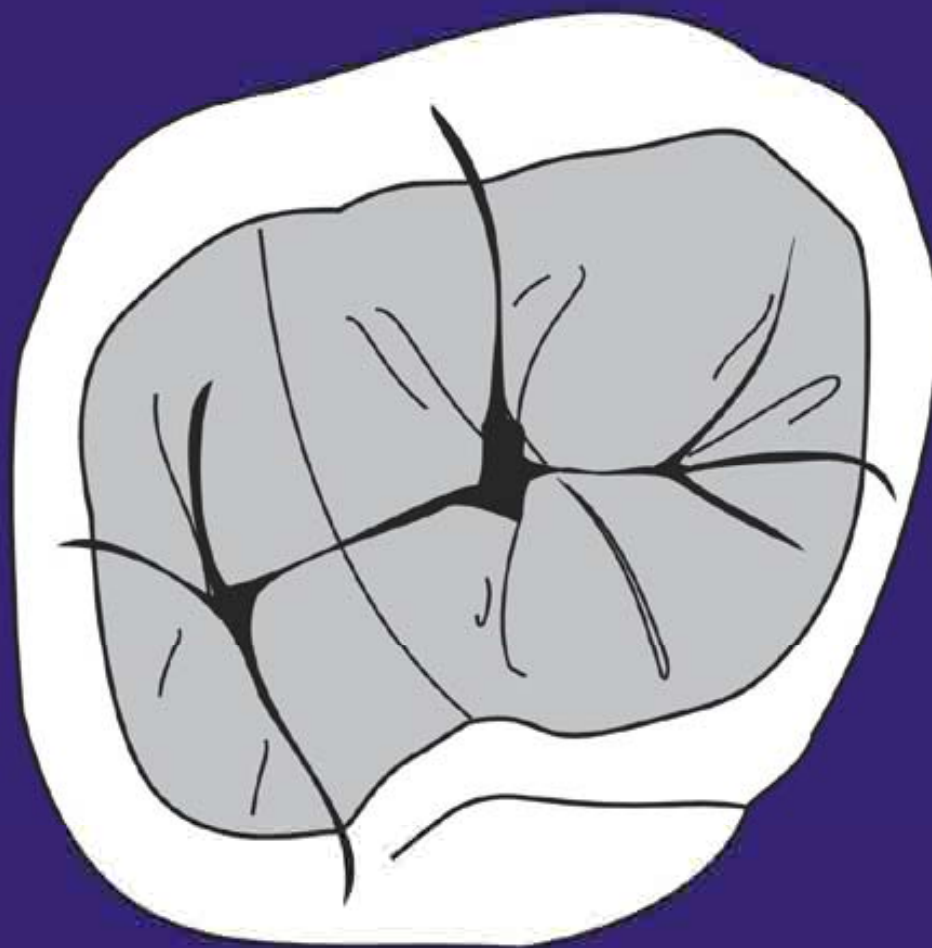
1/3 inter-
cuspal
distance

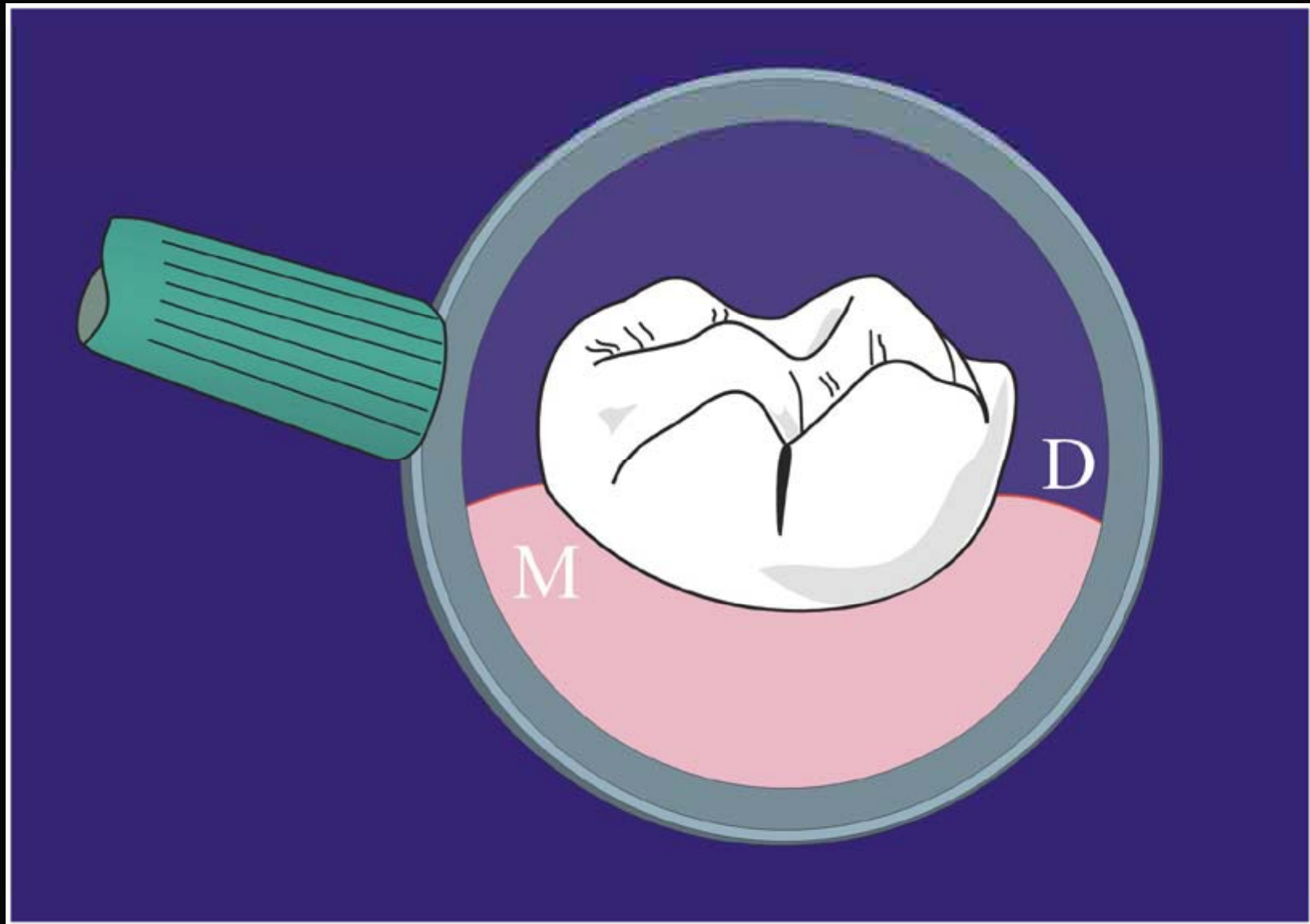
Mínima Preparación

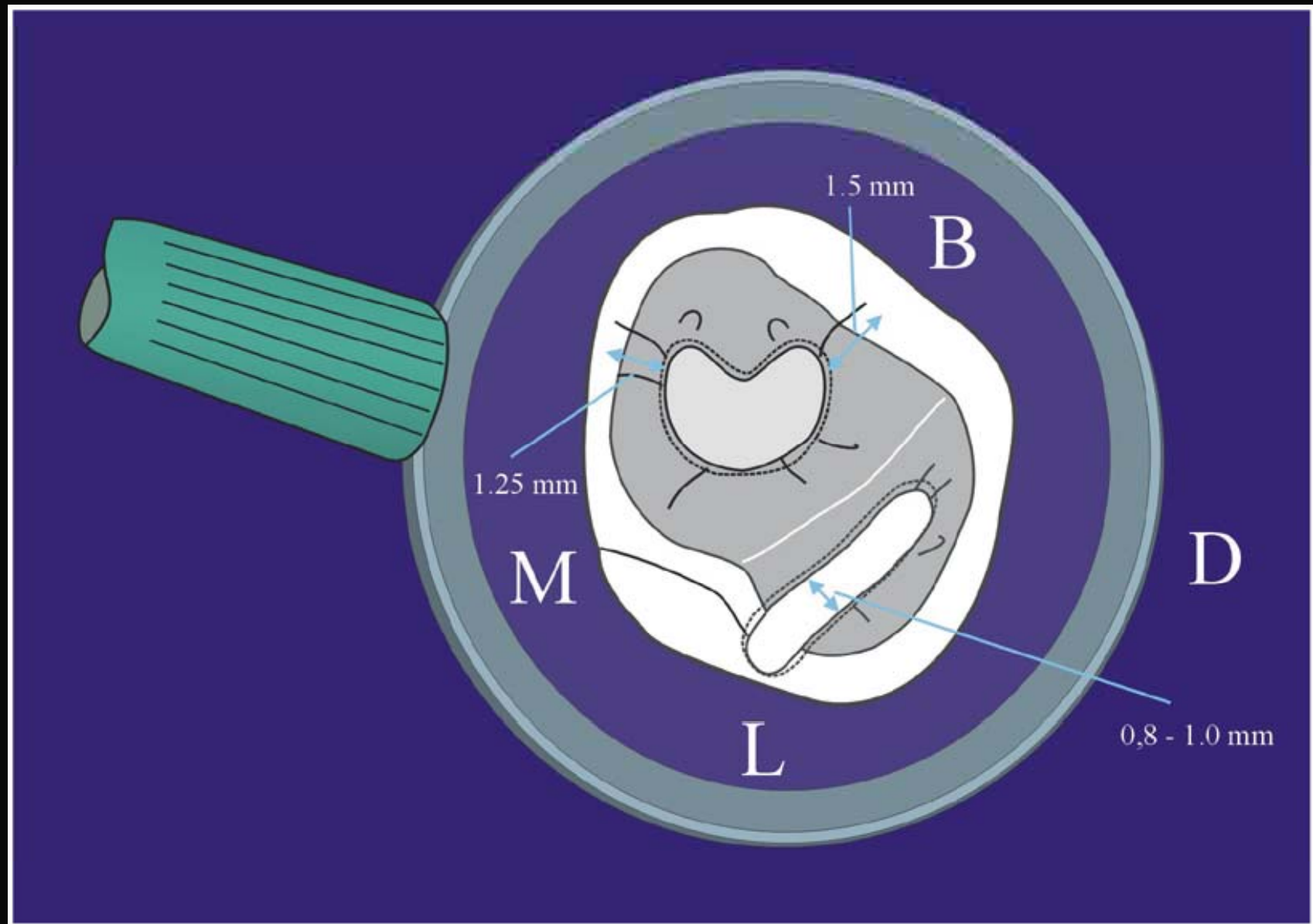
**PRIMER MOLAR
TEMPORAL SUPERIOR**

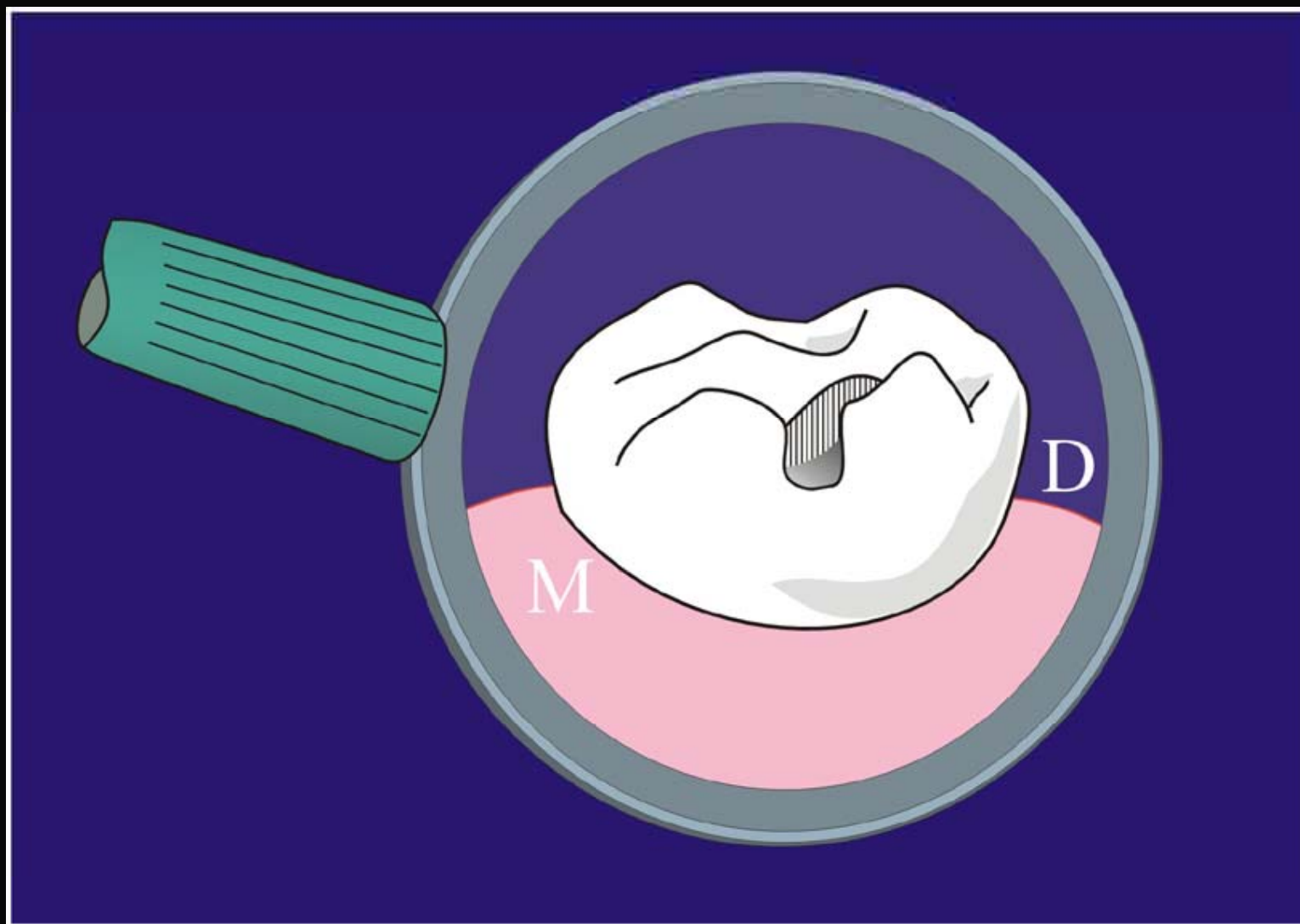


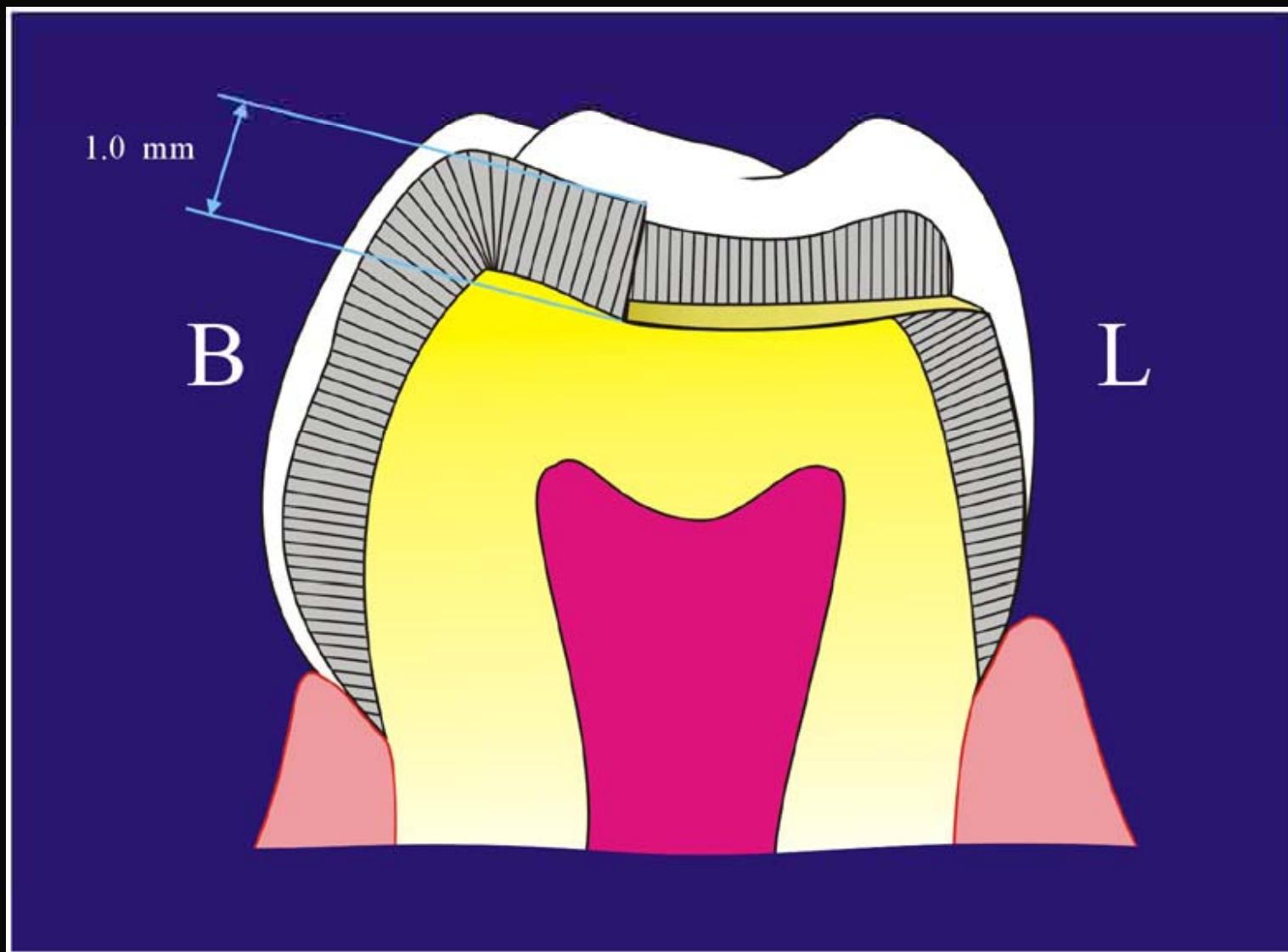
**SEGUNDO MOLAR
TEMPORAL SUPERIOR**

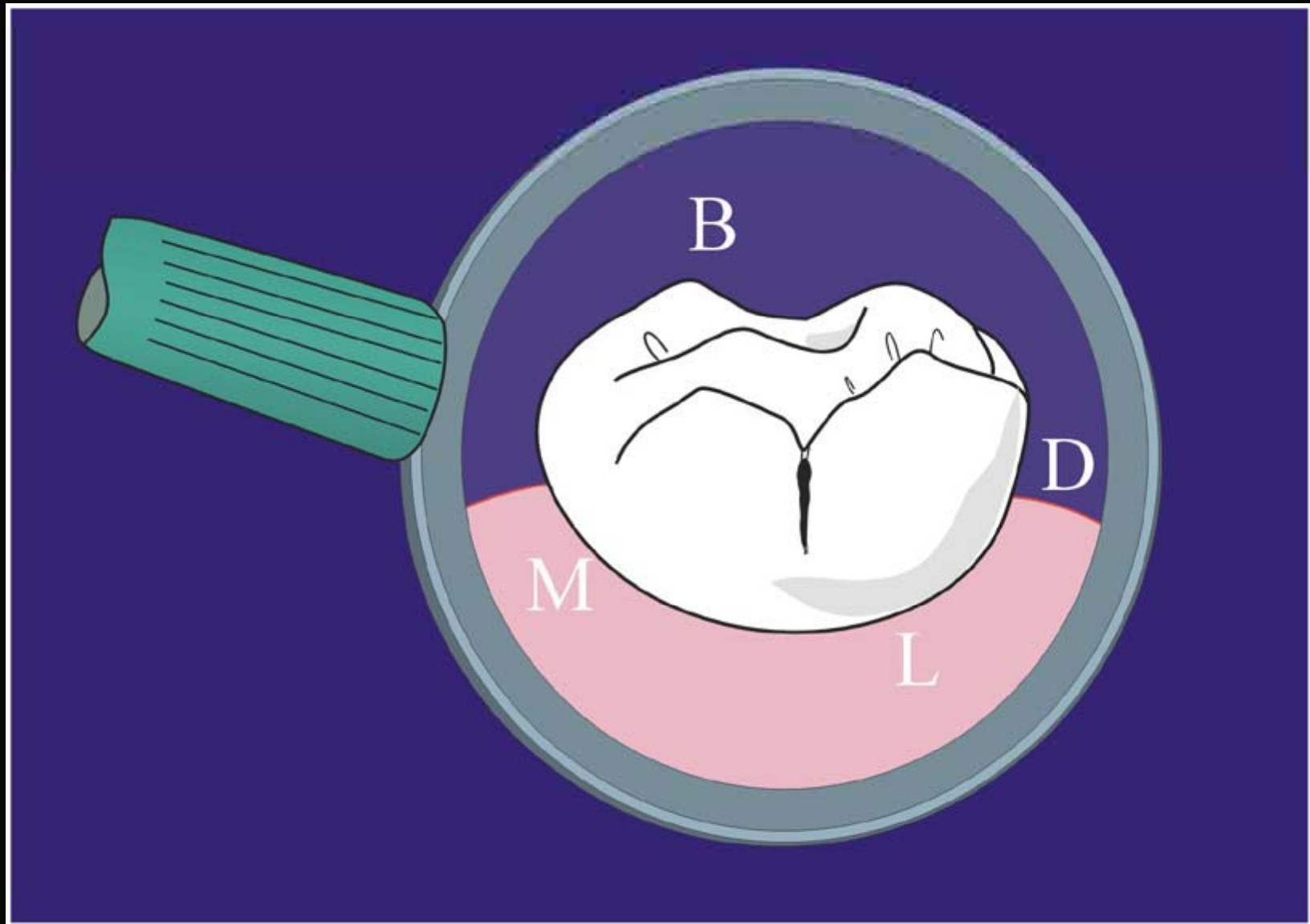


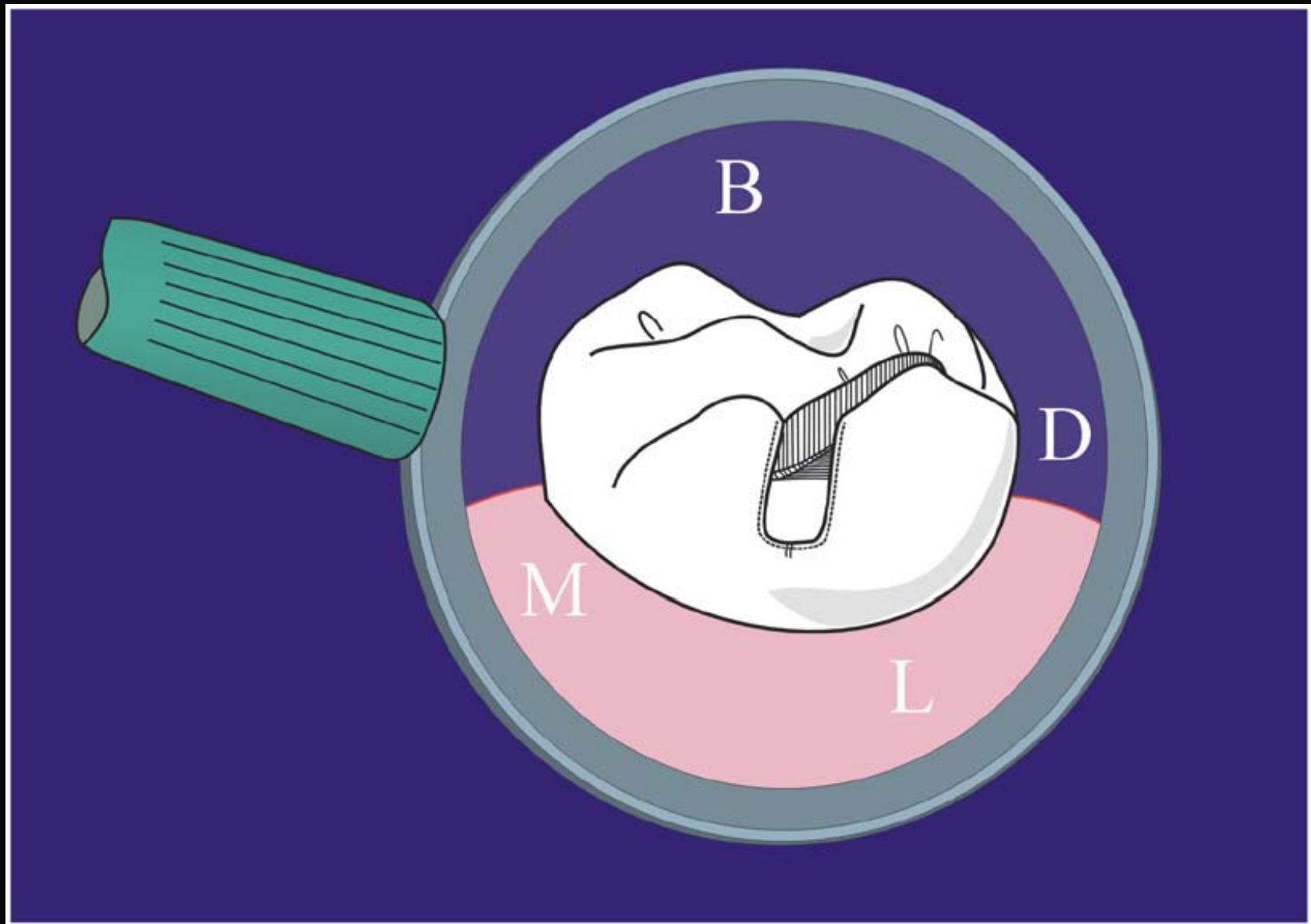


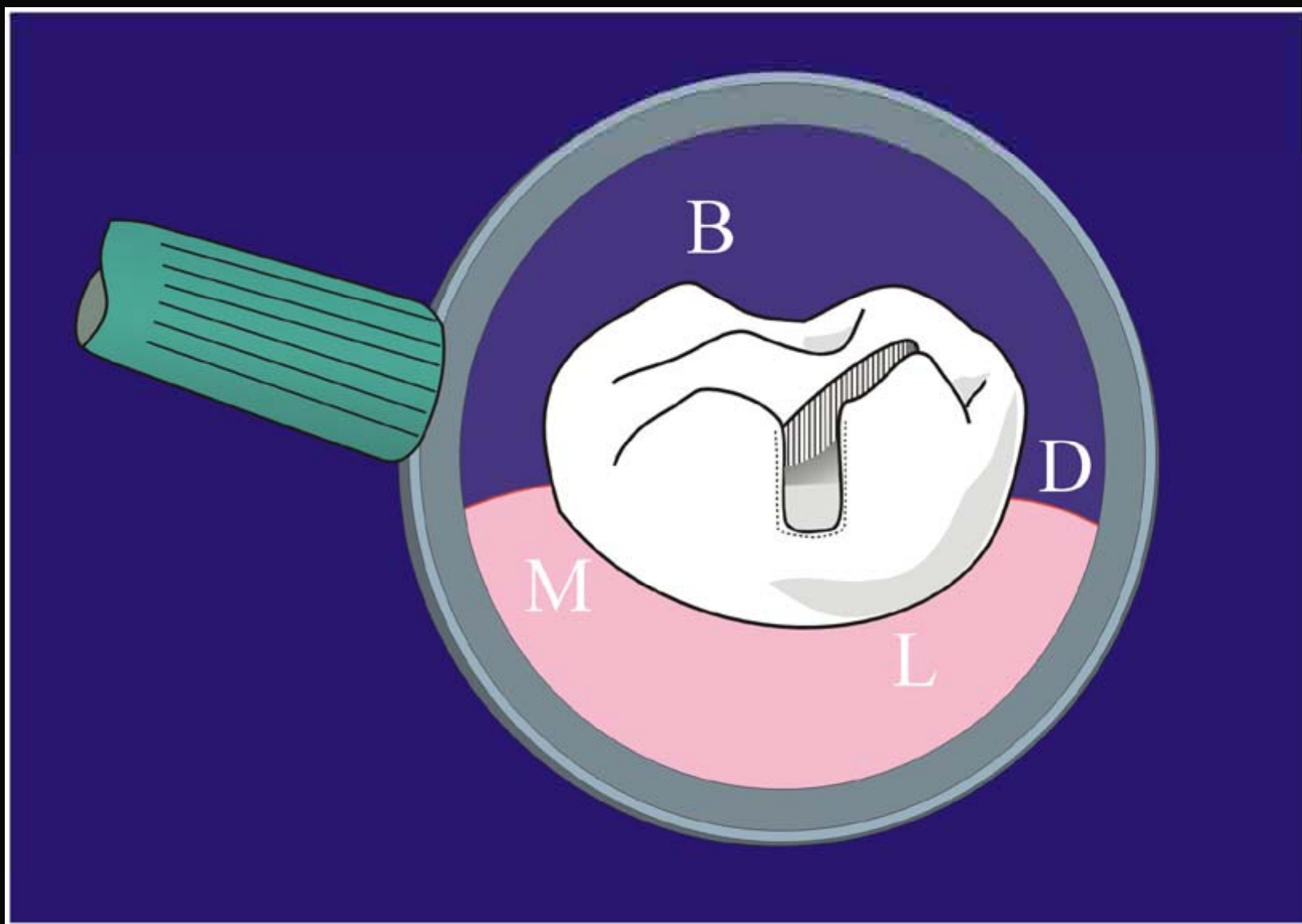


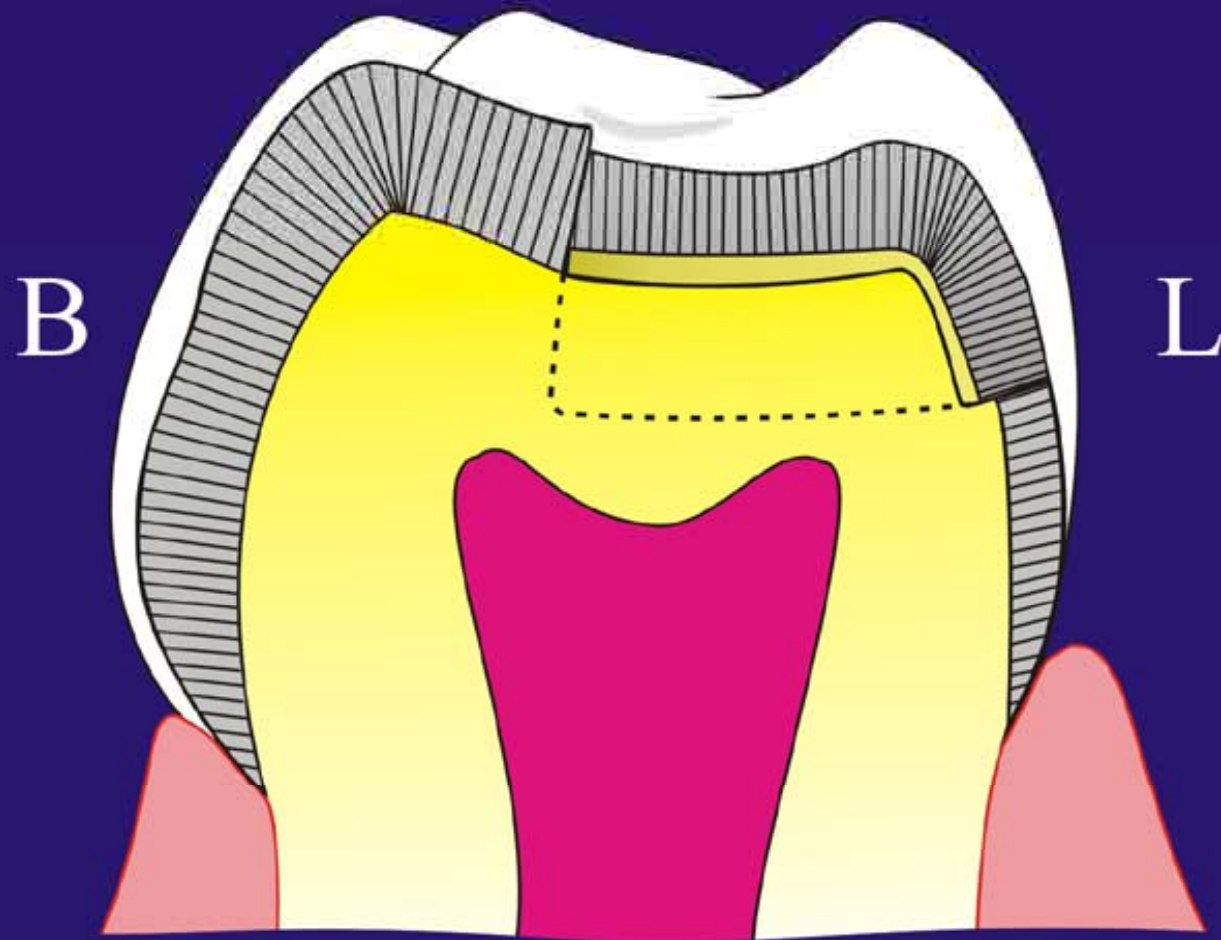






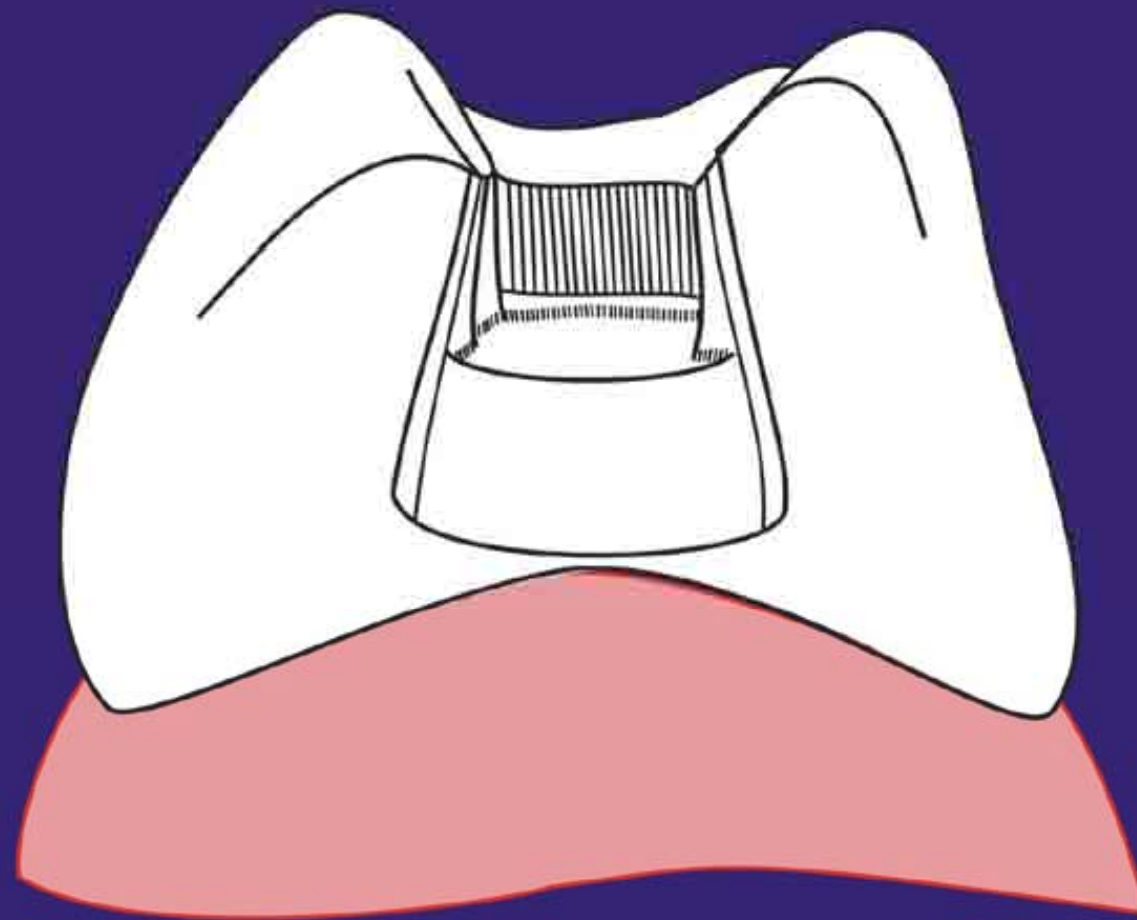




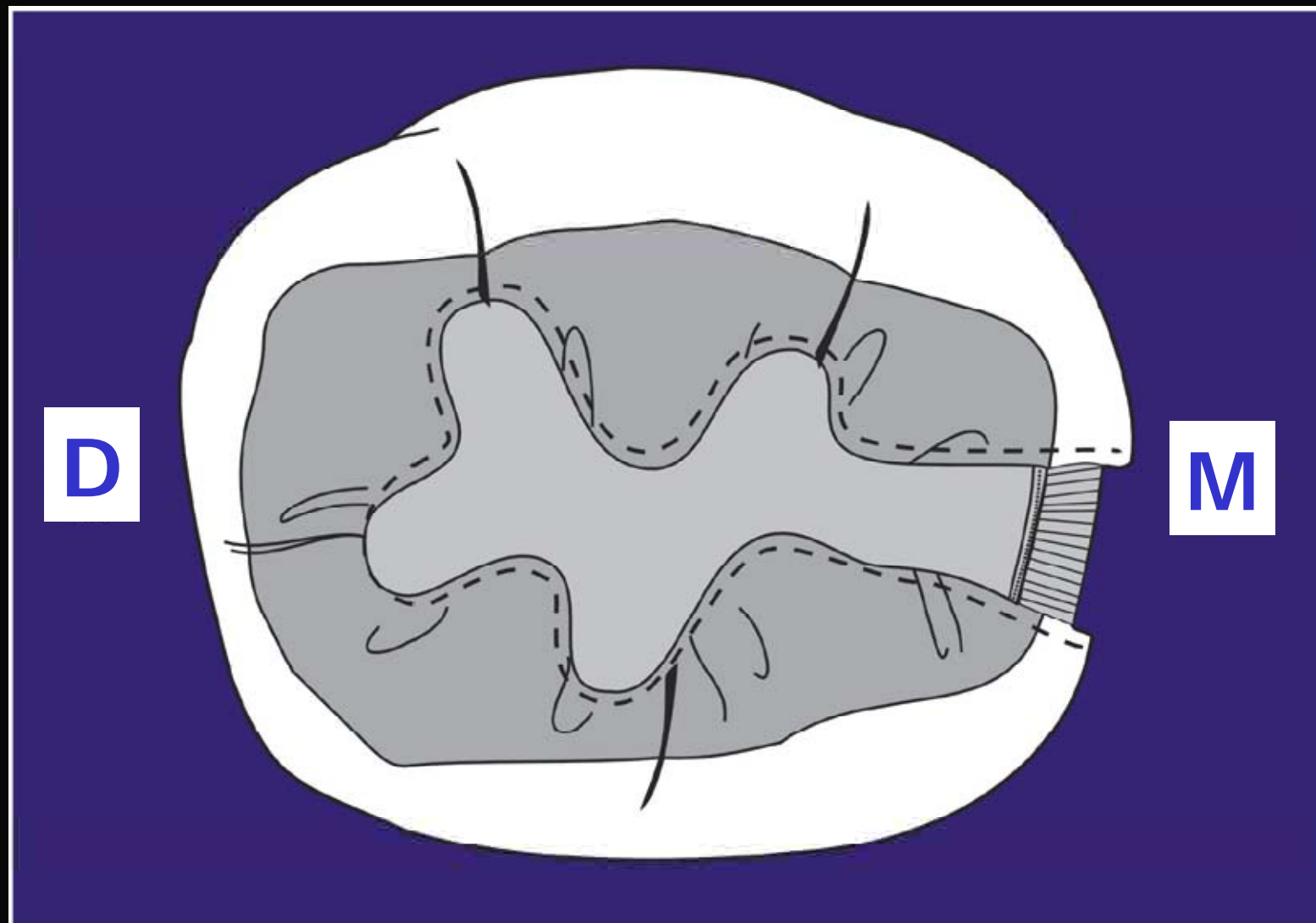


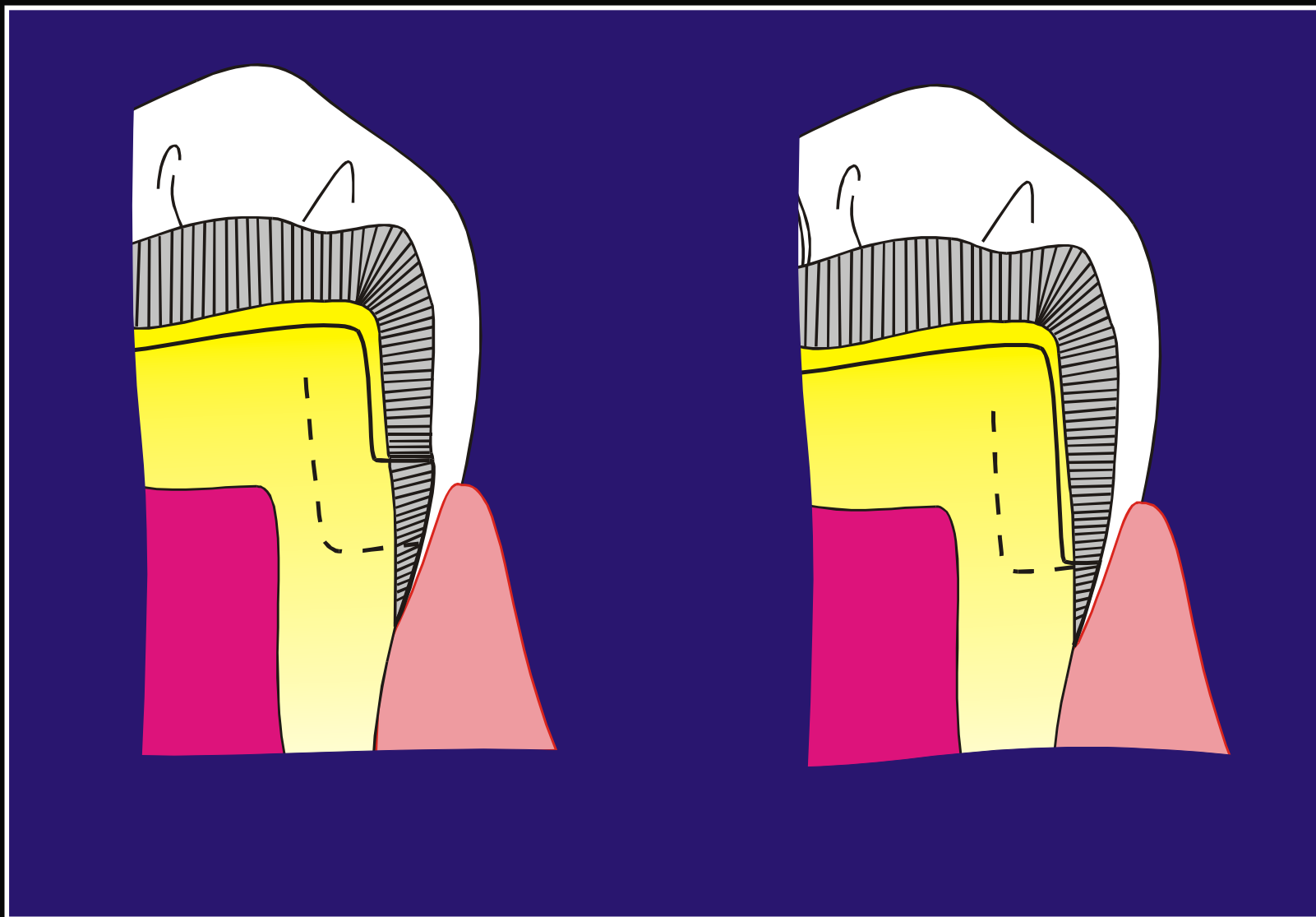
CAVIDADES

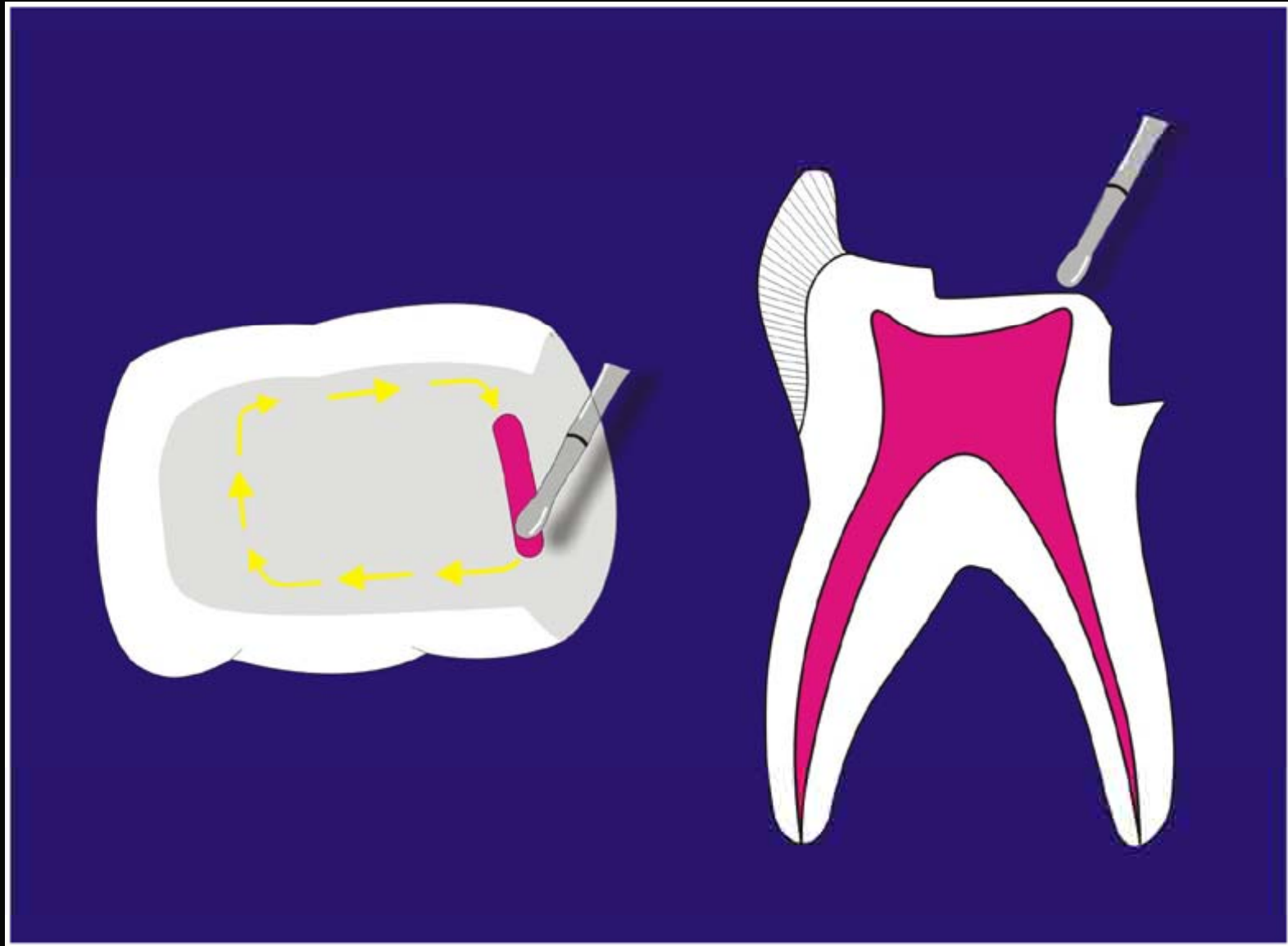
CLASE II



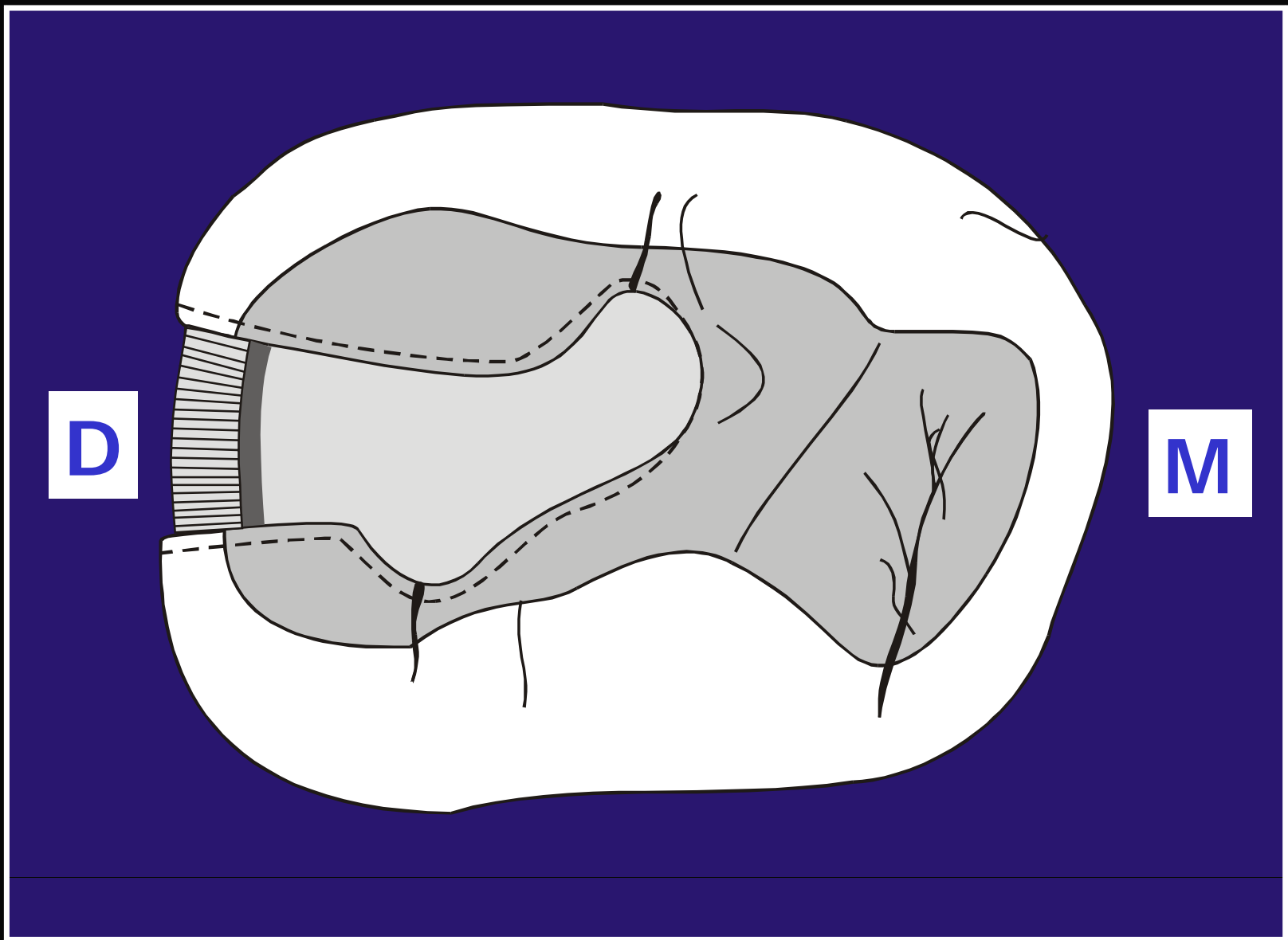
SEGUNDO MOLAR INFERIOR

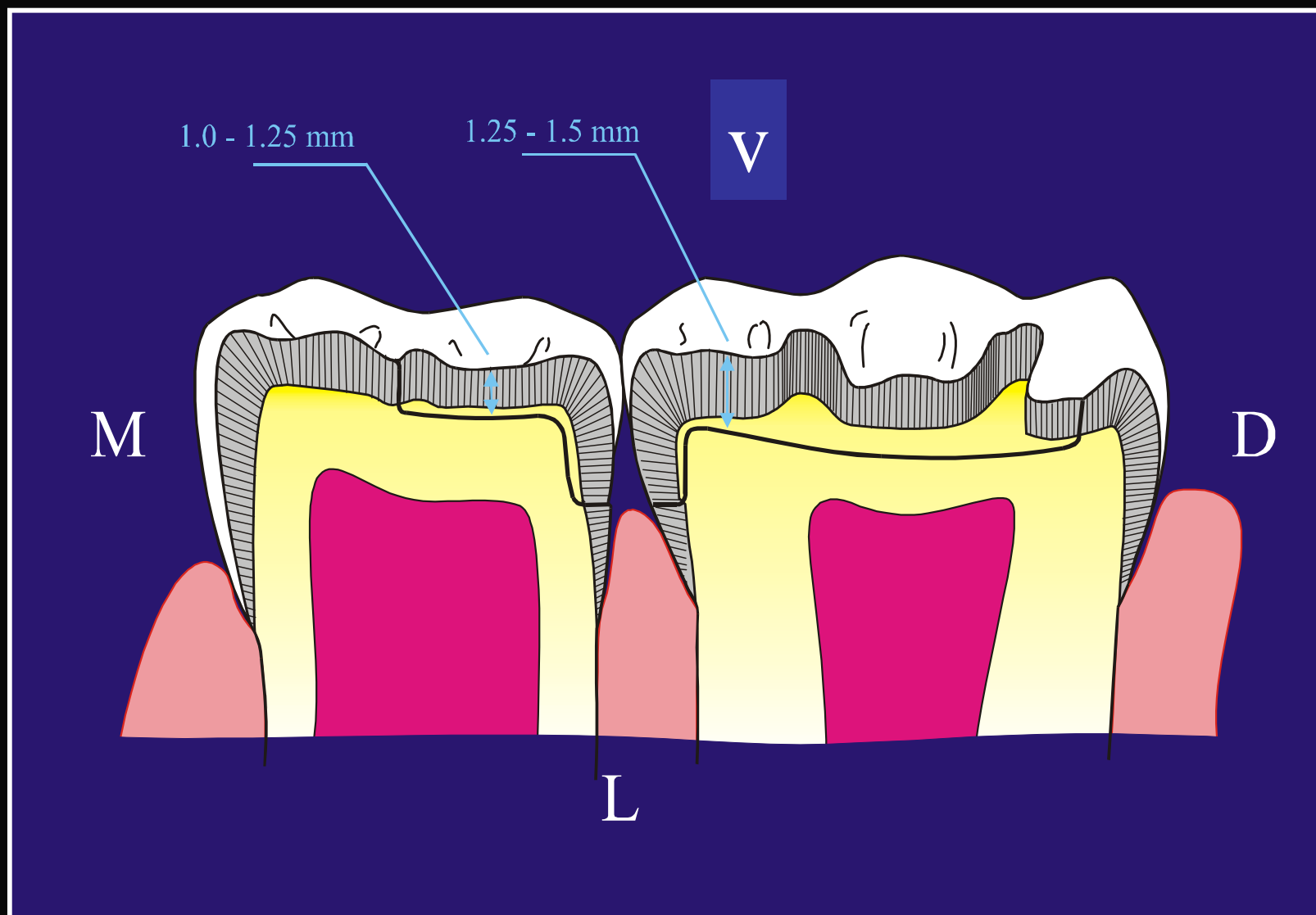




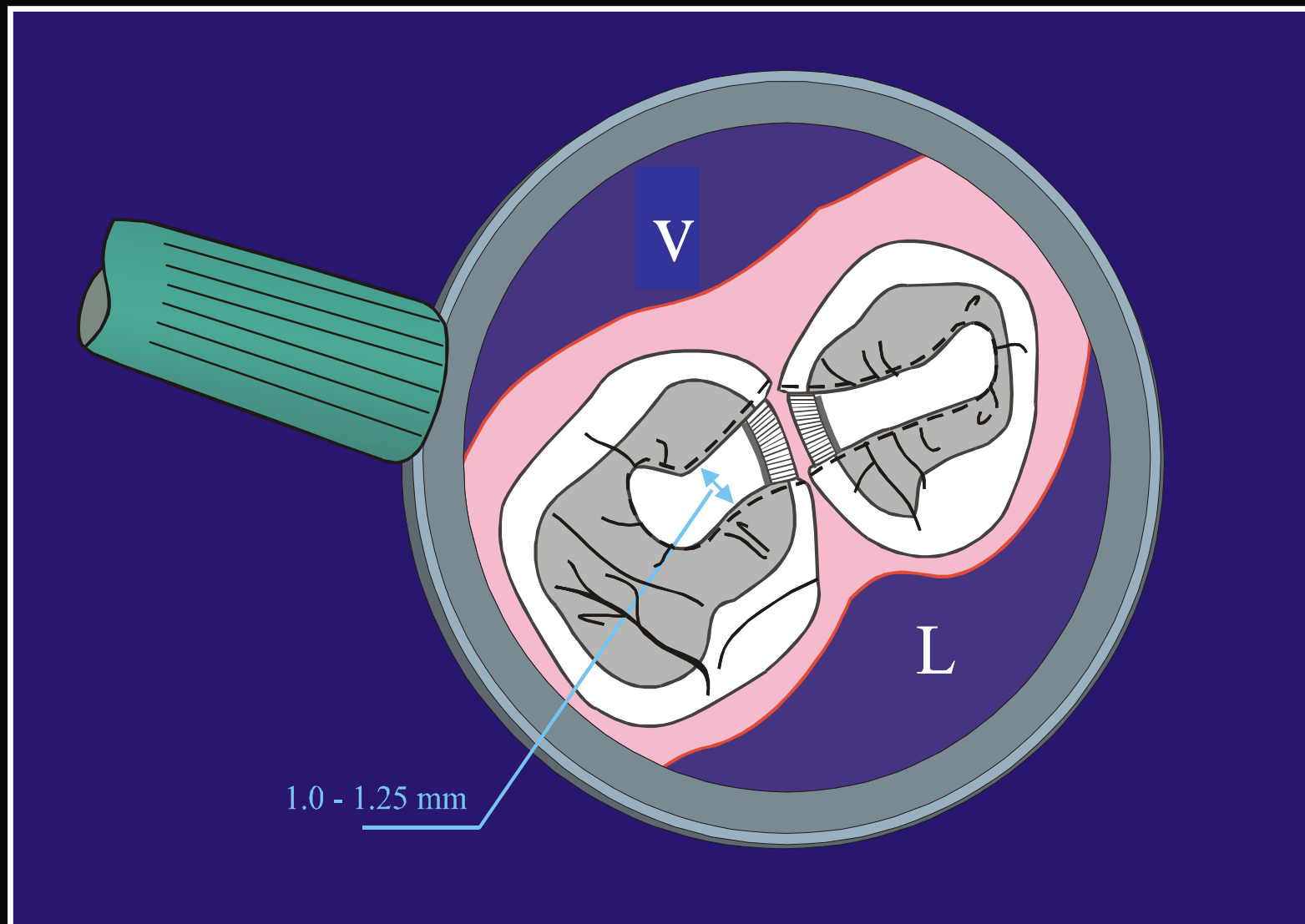


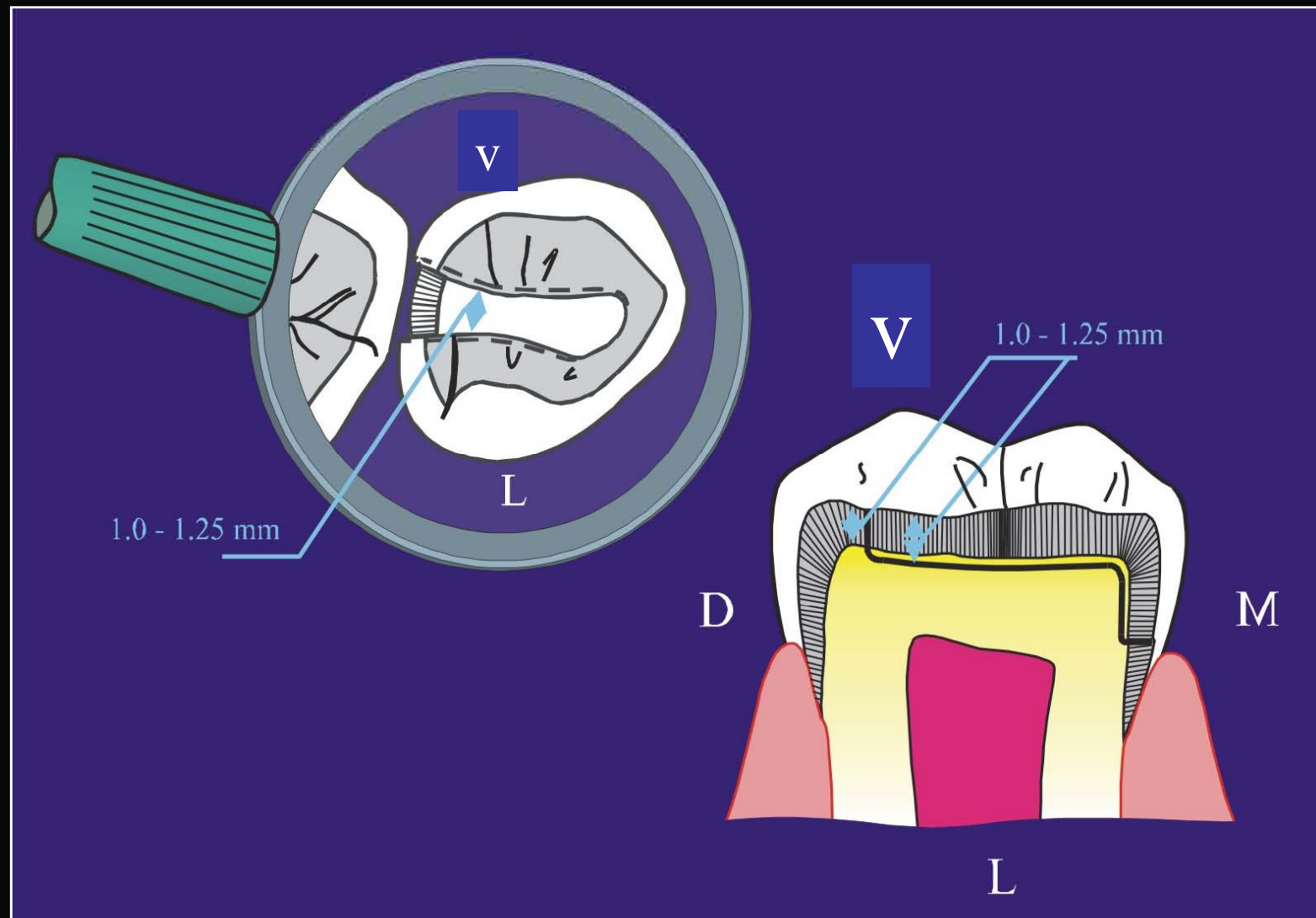
PRIMER MOLAR INFERIOR





PRIMER Y SEGUNDO MOLAR SUPERIOR

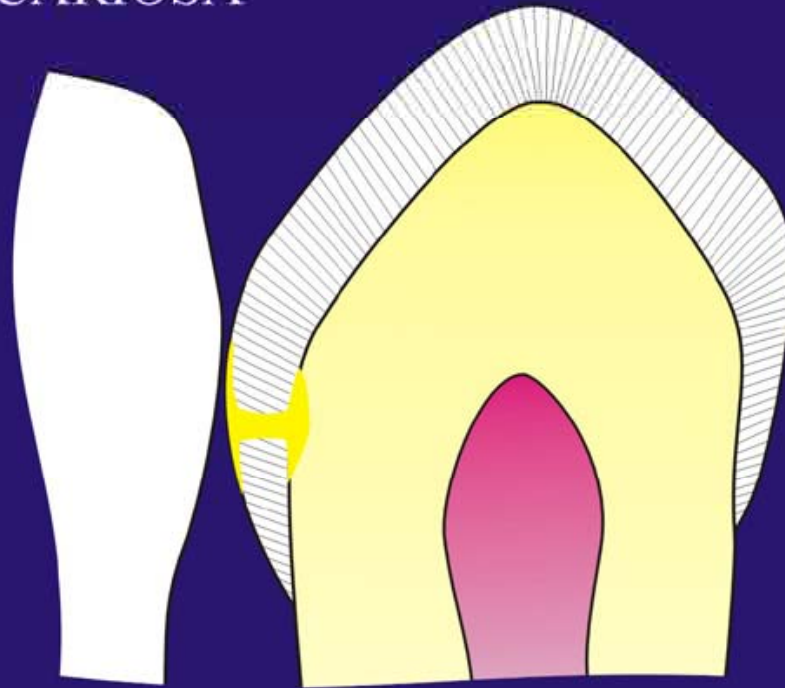




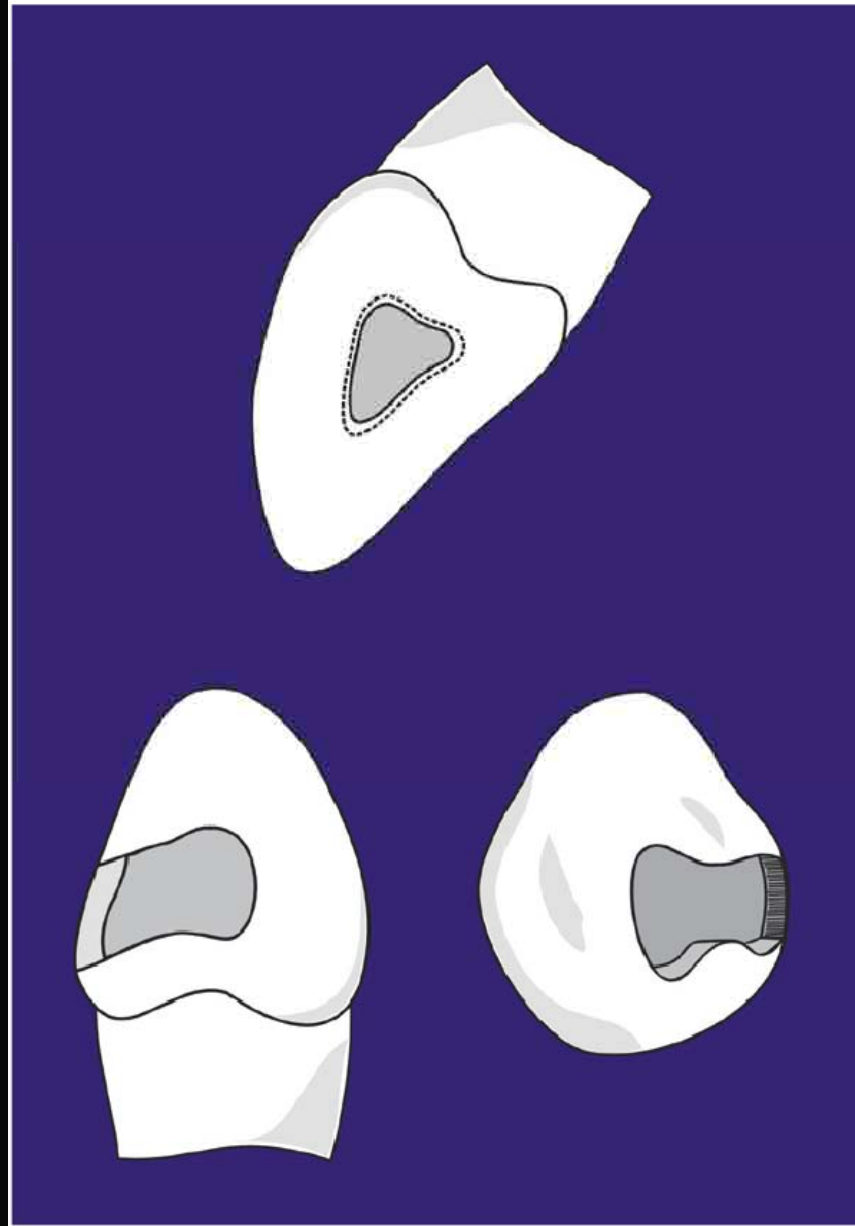
MATRICES INDIVIDUALES

**CAVIDADES CLASE III
PARA
Caninos**

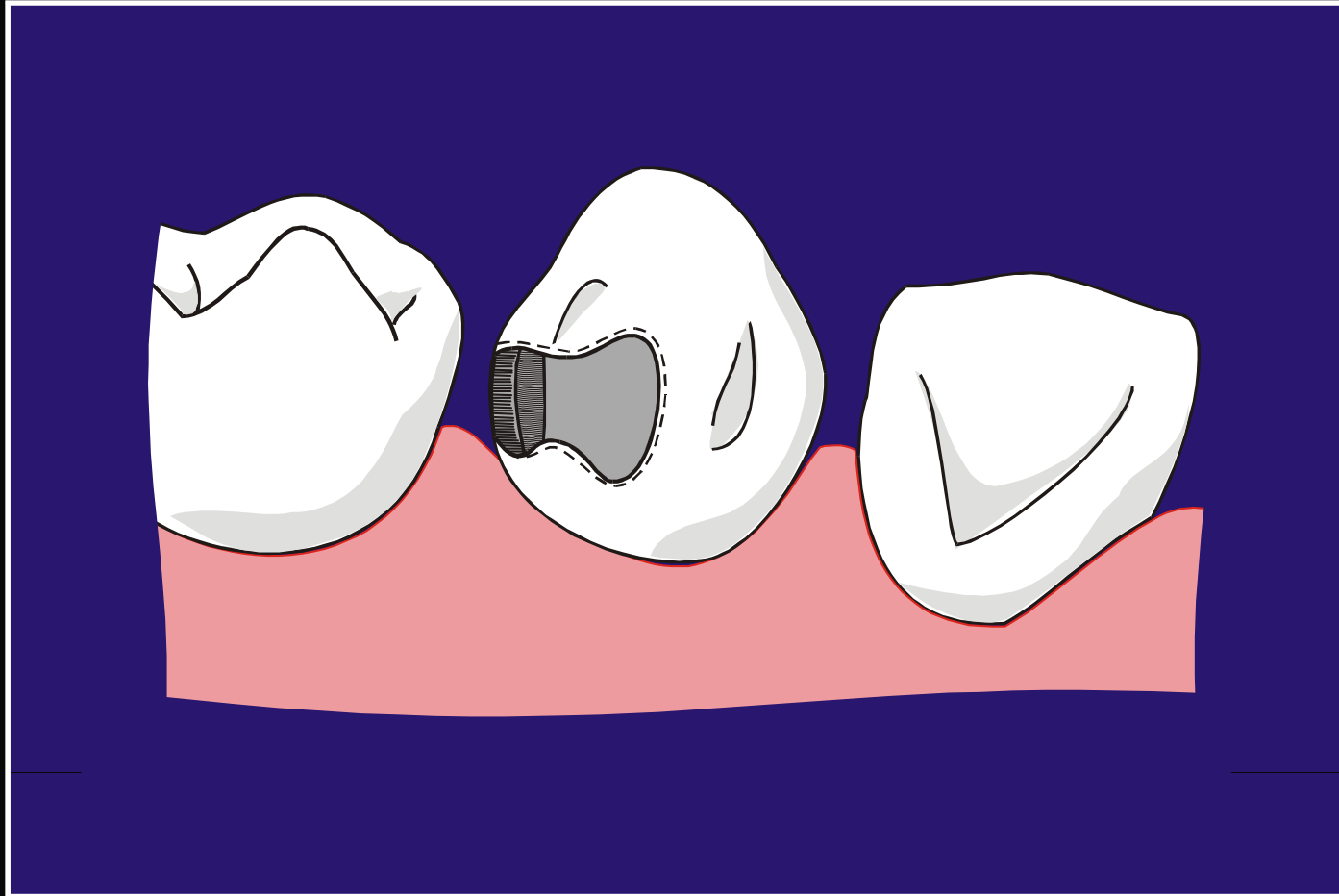
LESION CARIOSA



**Canino Temporal Mandibular Izquierdo
Sección Longitudinal M:D.**

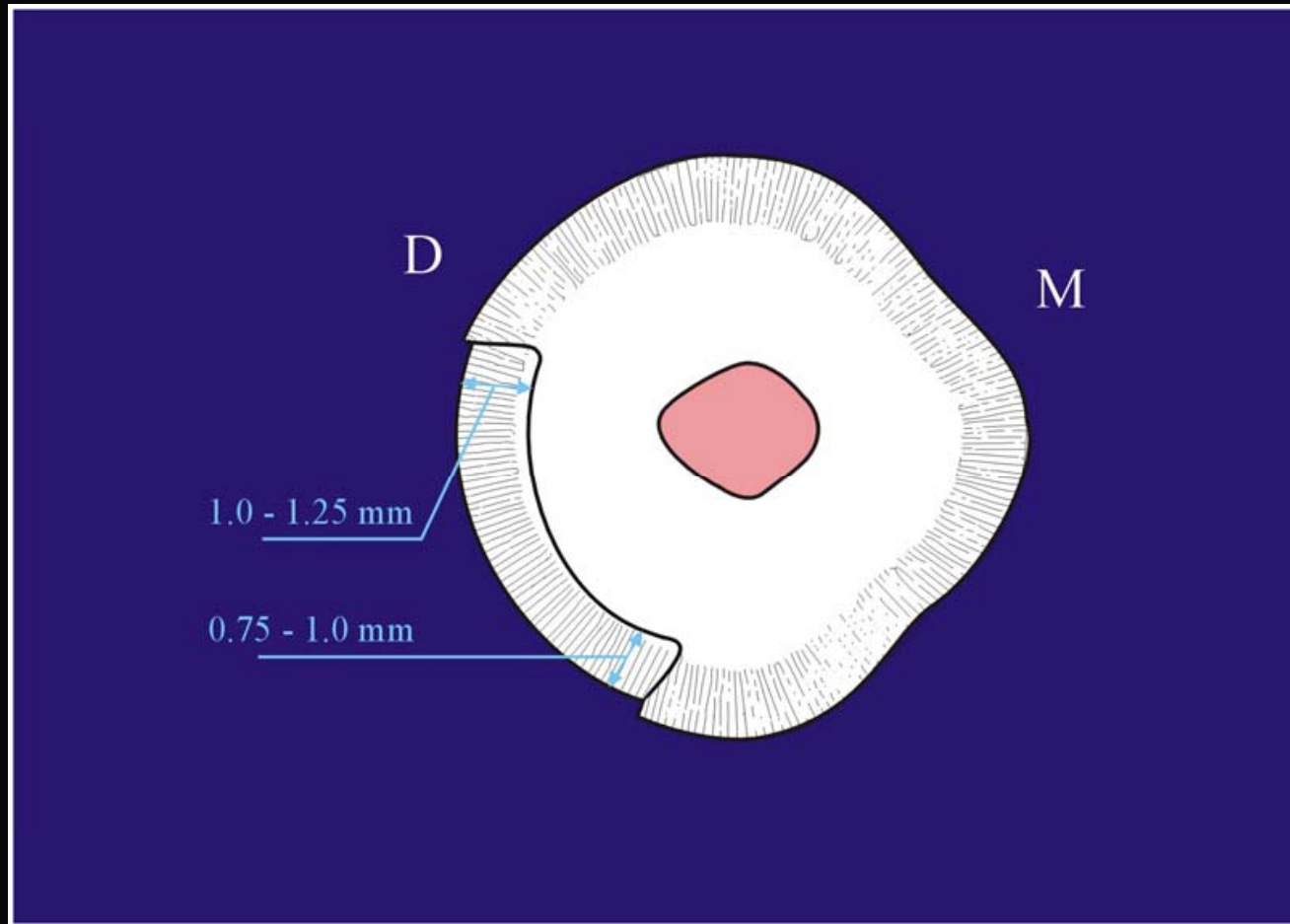


CLASE III (Modificada)

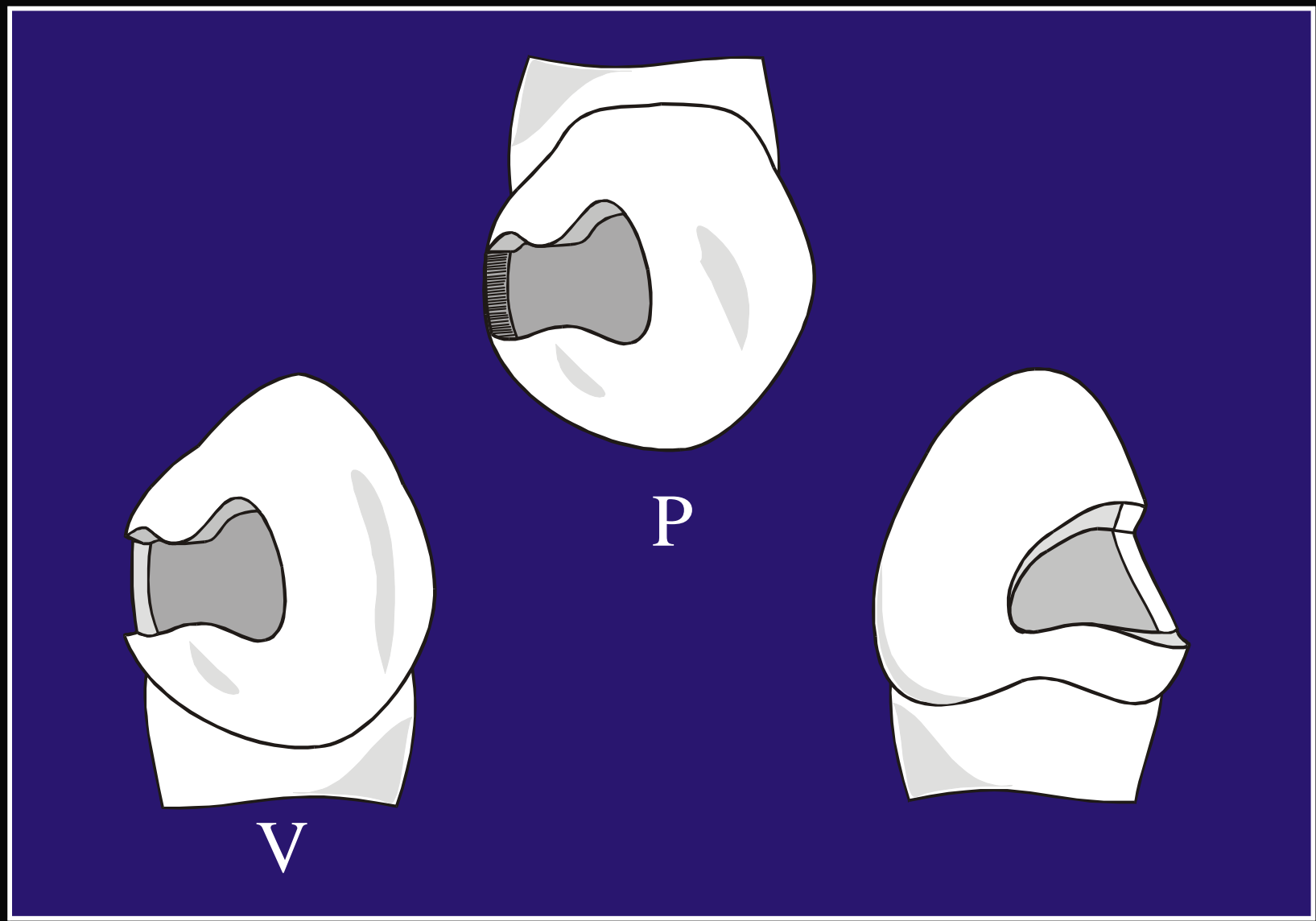


Canino izquierdo Mandibular. Vista Lingual

CLASE III (Modificada)

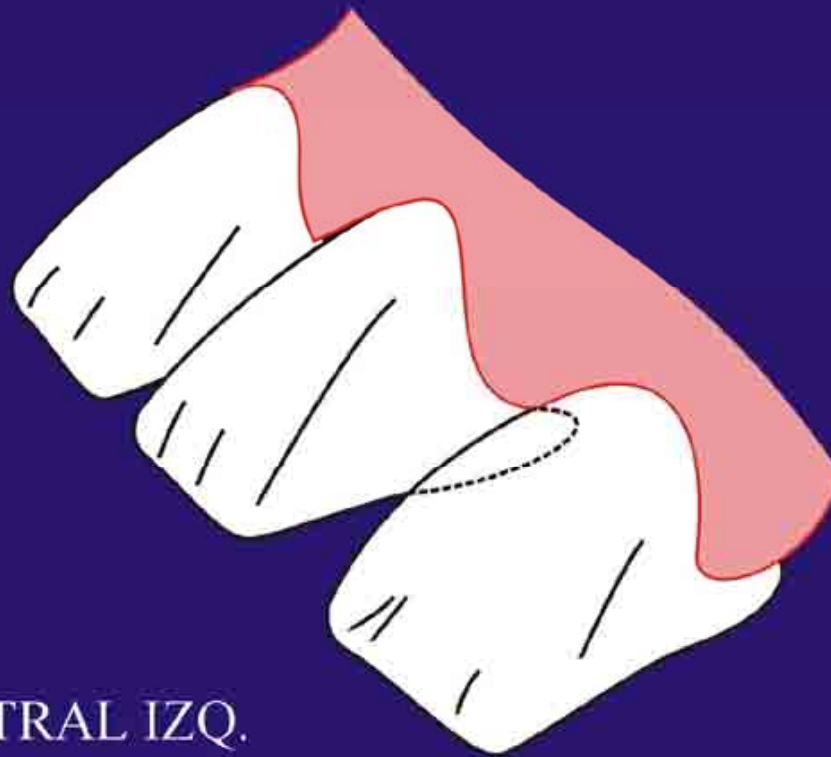


**Canino Temporal izquierdo Mandibular:
Sección Transversal**



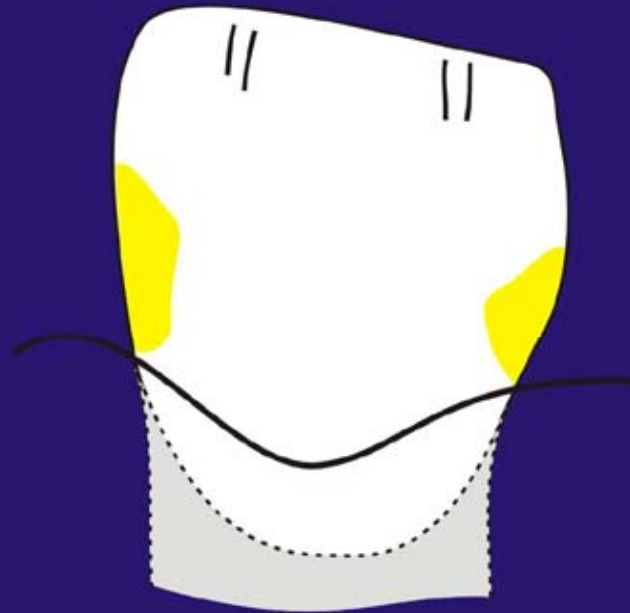
CAVIDADES
CLASE III
Incisivos

CLASE III



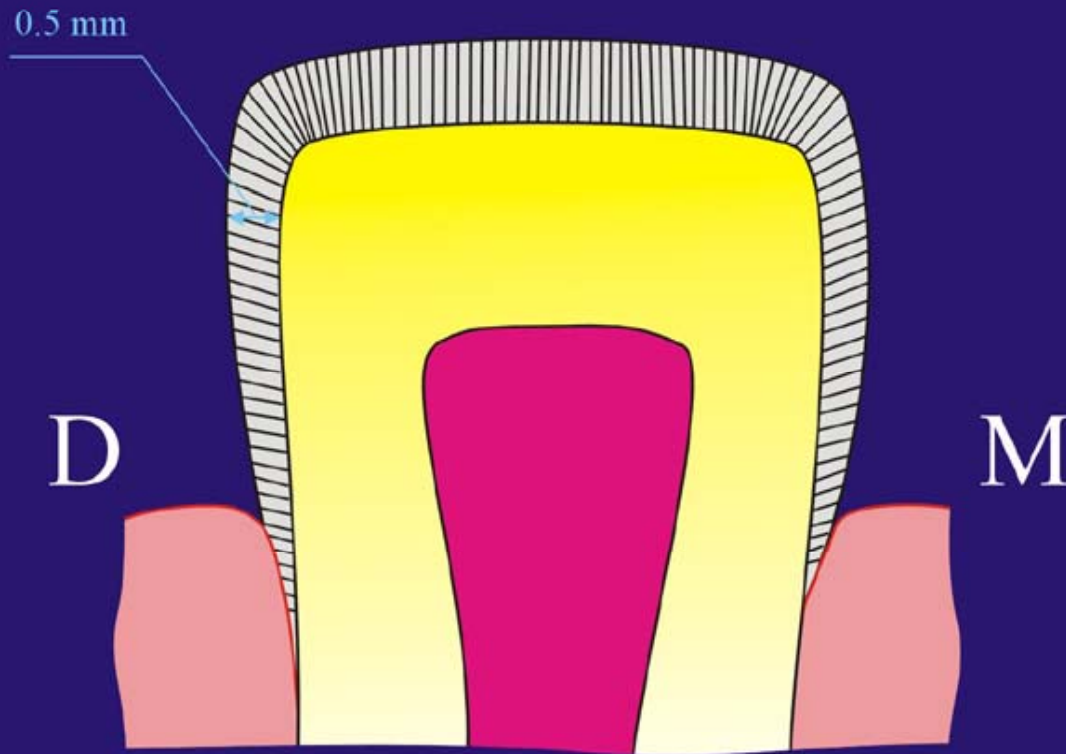
INCISIVO CENTRAL IZQ.
MANDIBULAR. CON DIASTEMA

LESION CARIOSA



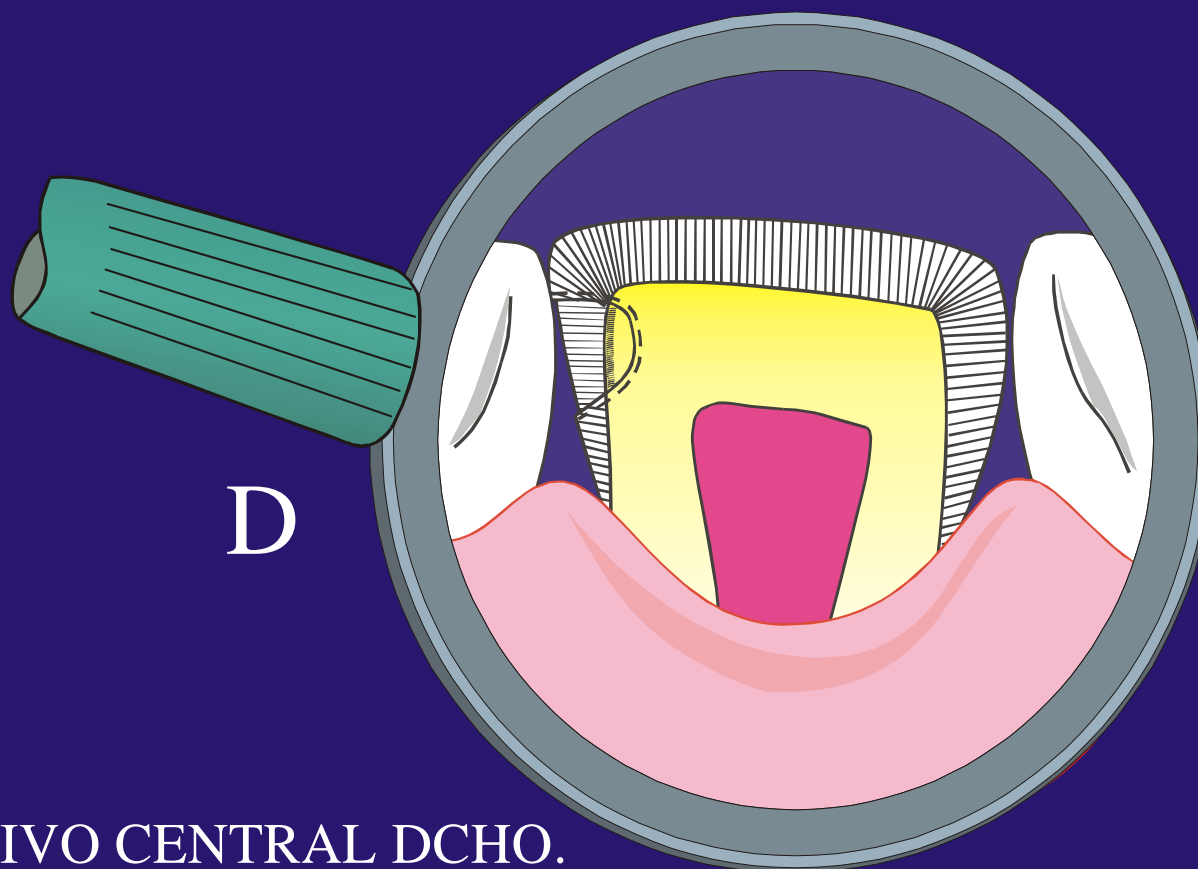
**INCISIVO LATERAL TEMPORAL IZQUIERDO
MANDIBULAR. SECCIÓN LONGITUDINAL M.D.**

CLASE III

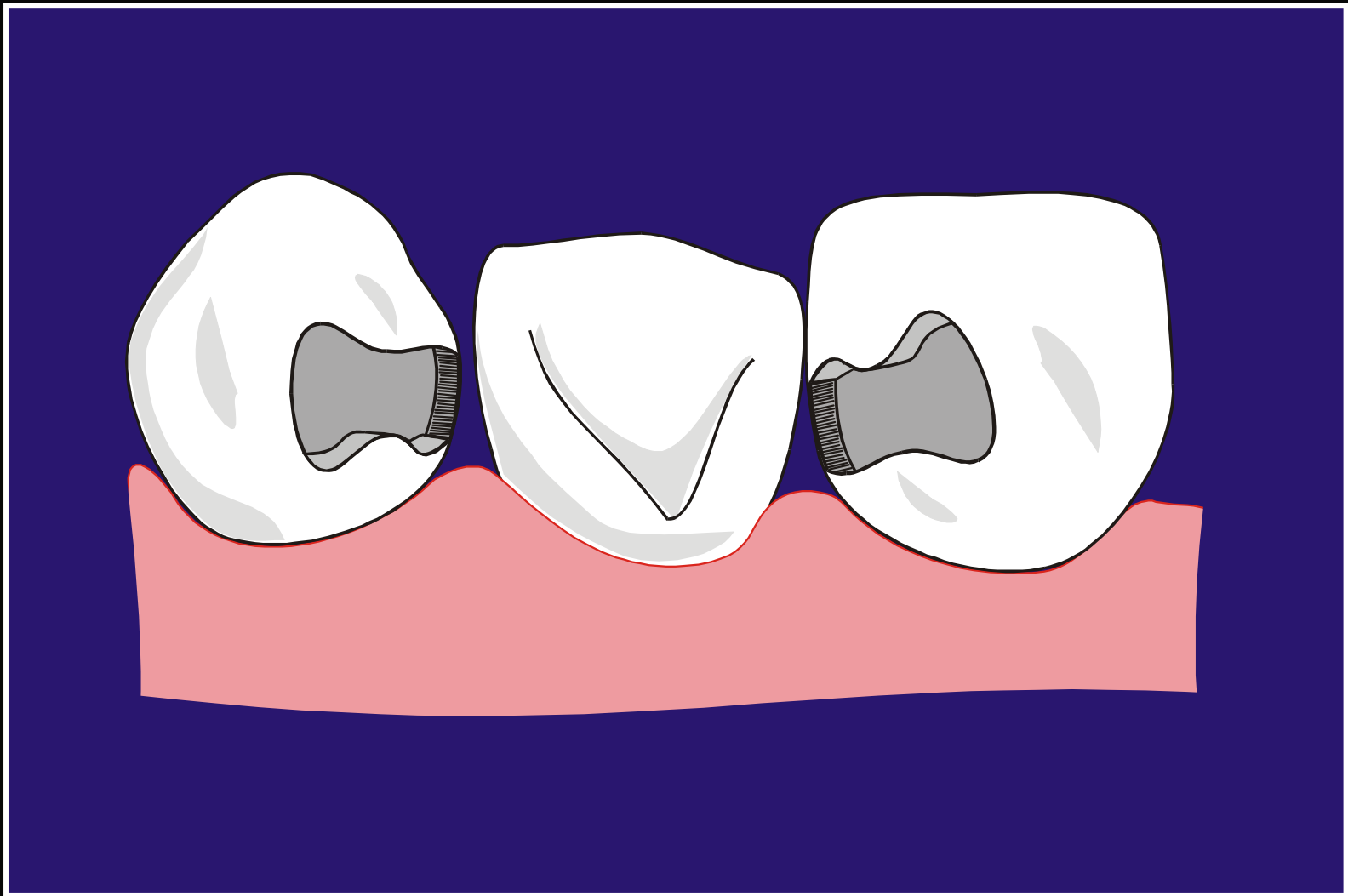


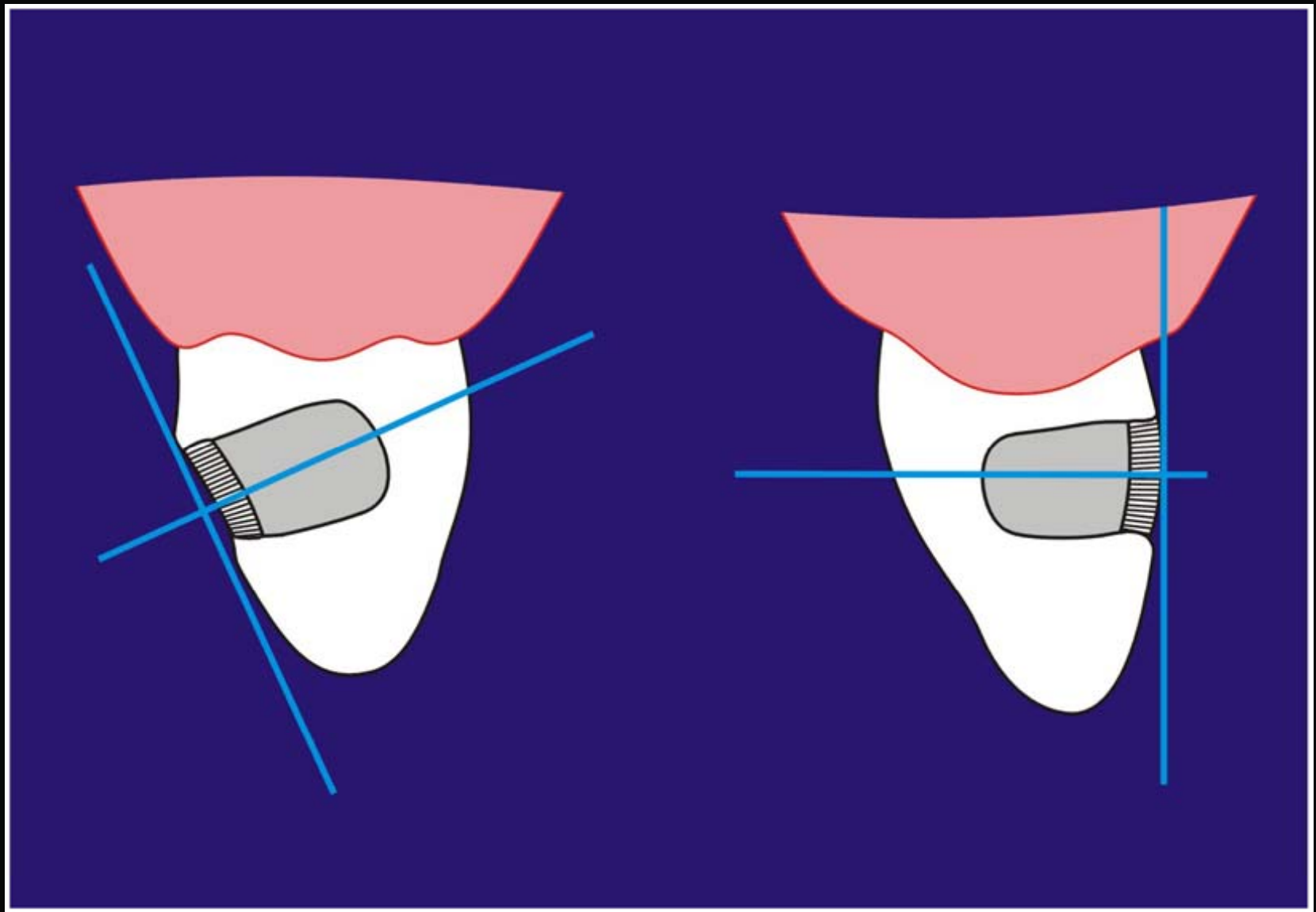
INCISIVO CENTRAL IZQUIERDOMANDIBULAR.
SECCION LONGITUDINAL M.D.

CLASE III

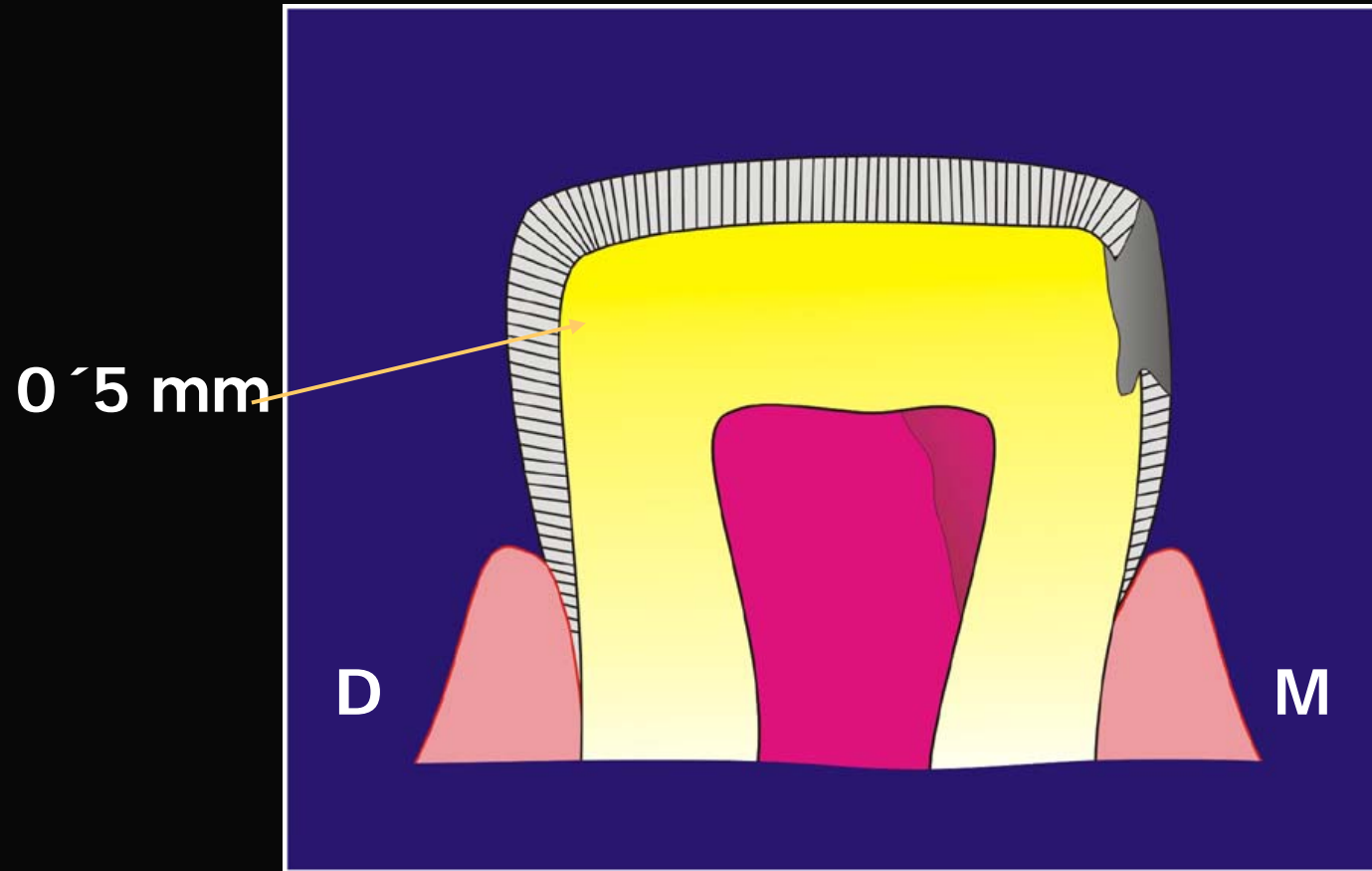


INCISIVO CENTRAL DCHO.
MAXILAR.
Sección Longitudinal M.D.



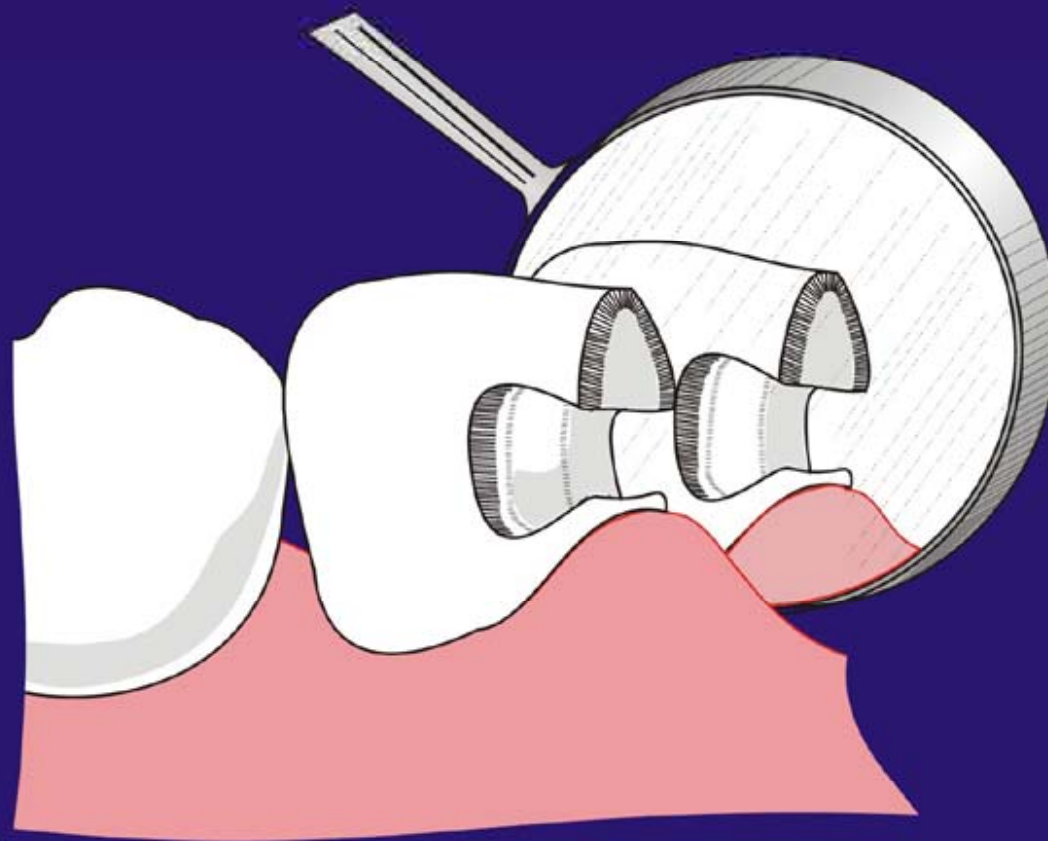


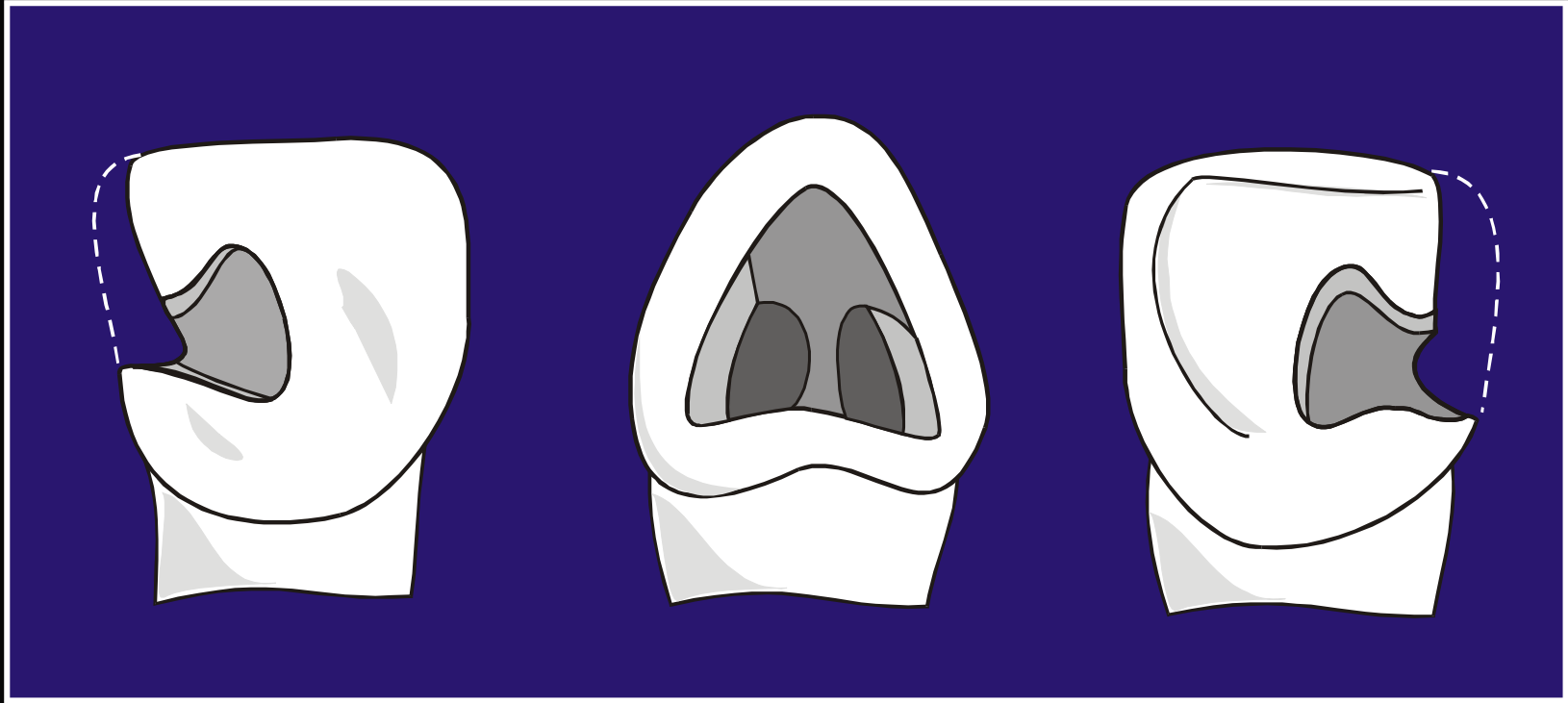
CLASE IV



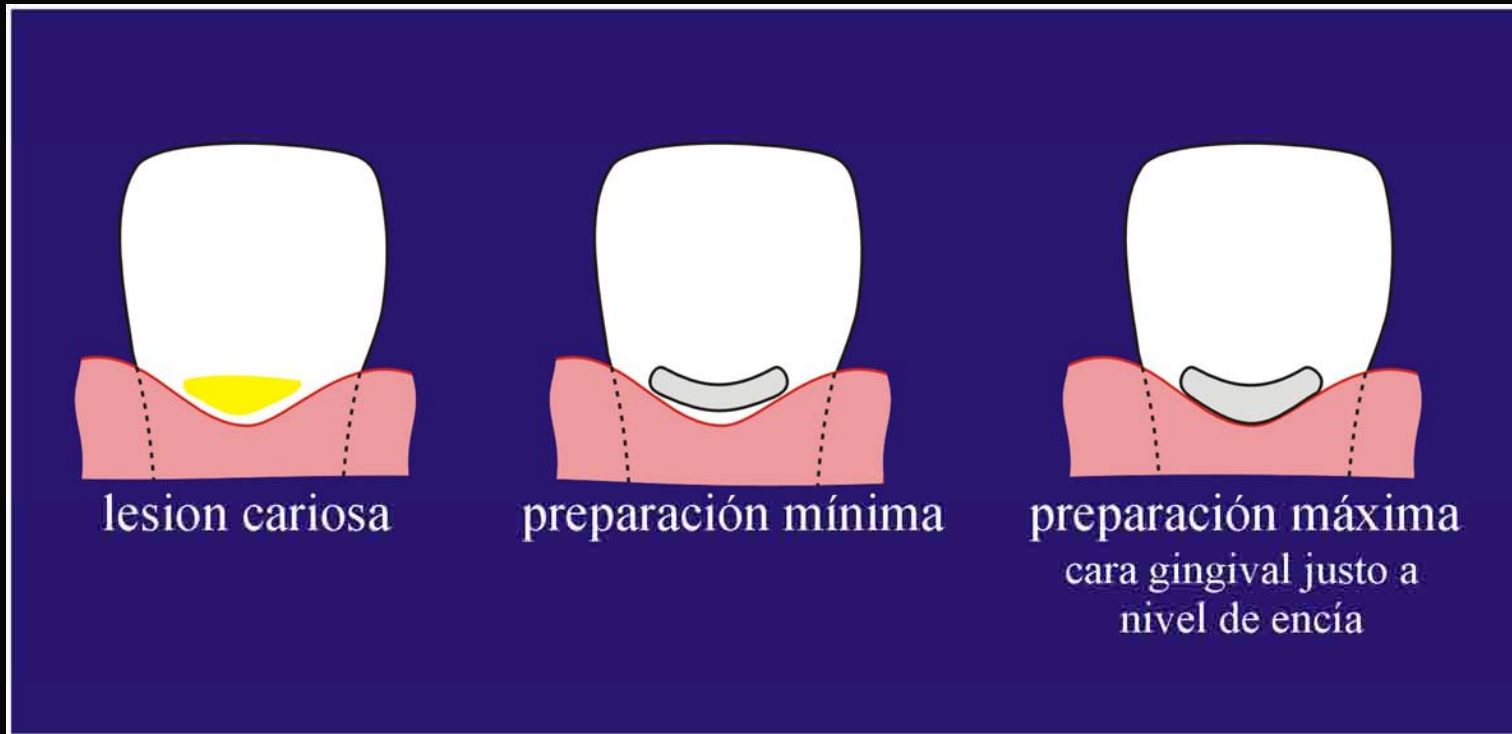
Incisivo Central
Izquierdo Mandibular
Sección Longitudinal M.D.

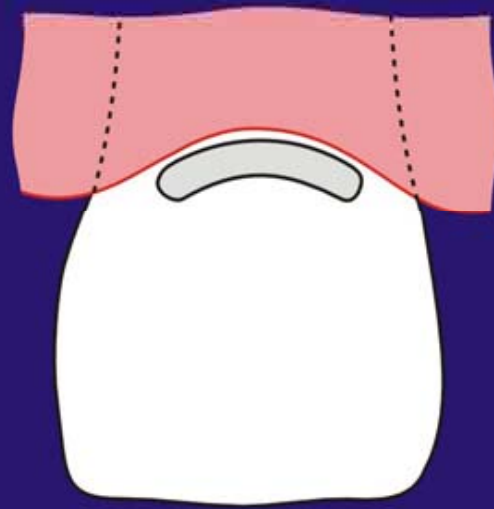
D



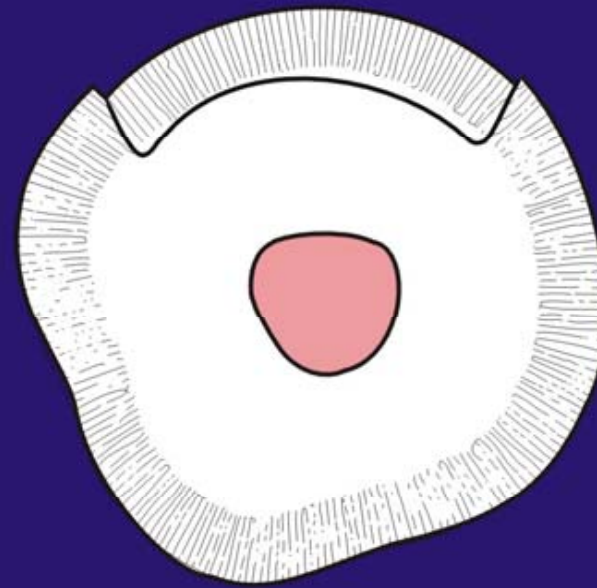


CLASE V





M



D

